

CASE REPORT

“SERPENT” IN THE BREAST

Talha Bin Saleem, Irfan Ahmed*

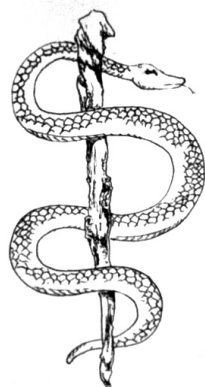
Airedale General Hospital, Keighley, West Yorkshire, United Kingdom, *Queens Medical Centre, Nottingham, United Kingdom.

Introduction: *Dracunculus medinensis* better known as guinea worm is the longest nematode infecting humans. Mature female worms migrate along subcutaneous tissue to reach the skin below the knee forming a painful ulcerating blister. Calcified male worm can occasionally be found in the retro peritoneum. Finding of a calcified worm in the breast tissue is very rare. **Material and methods:** We report a case of a fit and well African lady who was found to have a calcified guinea worm in the breast on a mammographic examination for investigation of a breast lump. **Conclusion:** Guinea worm can be included in the differential diagnosis of the breast lump especially in the endemic areas although the finding remains very rare.

Key Words: Guinea worm, *Dracunculus medinensis*, Breast lump, Serpent.

INTRODUCTION

Since ancient times *Dracunculus medinensis* (also known as guinea worm) infestations is known to infect human beings. It is described in the bible as a “fiery serpent”¹. The traditional doctor’s emblem of the staff and the snake (Figure 1) is usually believed to be the staff (the karykeion) of the Greek God *Asclepius (the God of Medicine)*. But in another opinion it is thought to be derived from the Jews wandering in Egypt suffering from the guinea worm infestation wherein they used a wooden peg to roll up the worm to extract it². This was also the first human parasite shown to have an arthropod intermediate host in 1869 by a Russian called Fedtschenko.



In 1986, when the world health assembly first adopted a resolution calling for the eradication of dracunculiasis (Guinea worm disease), an estimated 3.5 million persons in 20 countries had the disease, and approximately 120 million persons were at risk for infection³. By December 2001, annual incidence of dracunculiasis had decreased approximately 98%, and seven countries (Cameroon, Chad, India, Kenya, Pakistan, Senegal, and Yemen) in which dracunculiasis had been endemic previously had eliminated the disease.⁴

CASE REPORT

A 51 years old female of North African origin, presented in the surgical outpatient clinic with a painless lump in the right breast. She was fit and well and recently migrated from Kenya to England. On clinical examination she was found to have an irregular lump under the right nipple. There were no skin changes, nipple discharge or axillary lymphadenopathy. Mammogram showed a calcified Guinea worm under the right nipple without any suspicion of malignancy (Pictures 1 & 2). No treatment was offered and a repeat mammogram after one year showed the same findings. She was discharged from the clinic without any follow up and will be screened routinely as per national guidelines of screening for breast cancer.

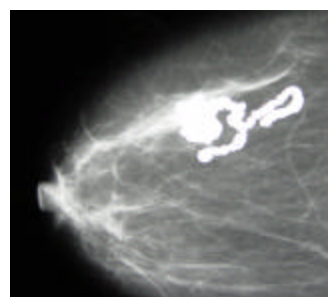


Figure-1

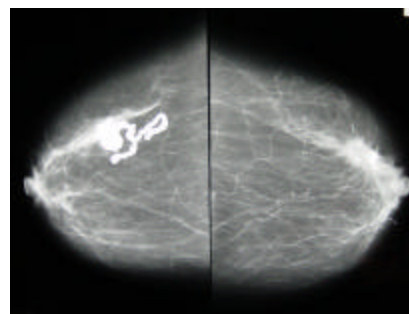


Figure-2

DISCUSSION

Dracunculiasis is a parasitic infection caused by *Dracunculus medinensis*. Persons become infected by drinking water from ponds contaminated by copepods (water fleas) that contain immature forms of the parasite. After ingestion of the infested water the larvae burrow through the duodenum to reach the retro peritoneum and take about 100 days to mature into adult male and female worms. They mate in the retroperitoneal space. The male worm dies and may later calcify. These calcified worms are sometimes seen on plain abdominal X-rays. It is very rare for the male worms to travel to other sub-cutaneous tissues. A year after entering the infected person, adult female worms (approximately 40 inches long) emerge through skin lesions, usually on the lower limbs, which frequently develop severe secondary bacterial infections. No effective treatment or vaccine for the disease exists, and infected persons do not become immune to future infections by the parasite. . Immature female worms can die in transit and calcify. Some ectopic sites like orbit, pericardium and

central nervous system for calcified worms have been reported⁵. The migration of the worm to the breast tissue remains very rare. Reports of breast filariasis have been made in the literature but none was found for the guinea worm⁶.

CONCLUSION

Finding of a calcified worm in the breast tissue is very rare. It may add to the differential diagnosis of sub-cutaneous lumps in the endemic areas.

REFERENCES

1. Holy Bible, King James version. Numbers 21.6
2. Haeger K. History of Surgery. 1988; AB Nordbok Gothenburg Sweden. Page 39.
3. Hopkins DR, Azam M, Roiz-Tibene, Kappus KD. Eradication of dracunculiasis from Pakistan. Lancet 1995; 346:621-4
4. WHO paper. Progress towards Global Dracunculiasis Eradication, June 2002. JAMA 2002; 288(22):2817-2818.
5. Worrell DA, Cox TM, Firth JD, Benz FJ. Oxford text book of medicine. Oxford University press 2003.
6. Sahai, K; Kapila, K; Verma, K; Parasites in fine needle breast aspirates-assessment of host tissue response. Postgraduate Medical Journal 2002, 78(917):165-167.

Address for correspondence: Dr Talha Bin Saleem, Department of General Surgery, Airedale General Hospital, Keighley. BD20 6TD West Yorkshire. Tel: 0044 1535 652 511, 0044 1535 654 148, Fax: 0044 1535 292 240
Email: kittoo68@hotmail.com