

ORIGINAL ARTICLE

MORPHOLOGICAL PATTERNS IN CHILDREN WITH GANGLION RELATED ENTERIC NEURONAL ABNORMALITIES

Nausheen Henna, Abdul H Nagi, Muhammad A Sheikh*, Mahmood Shaukat**

Department of Morbid Anatomy and Histopathology, University of Health Sciences, Lahore, *Department of Paediatric Surgery, Institute of Child Health and Children Hospital, **King Edward Medical University, Lahore, Pakistan

Background: Hirschsprung's Disease (HD) is a developmental disorder of enteric nervous system characterised by the absence of ganglion cells in submucosal (Meissner's) and myenteric (Aurbach's) plexuses of distal bowel. The purpose of the present study was to observe and report the morphological patterns of ganglion related enteric neuronal abnormalities in children presented with clinical features of (HD) in a Pakistani population. **Methods:** A total of 92 patients with clinical presentation of HD were enrolled between March 2009 and October 2009. Among them, 8 were excluded according to the exclusion criteria. After detailed history and physical examination, paraffin embedded H and E stained sections were prepared from the serial open biopsies from colorectum. The data was analysed using SPSS-17. Frequencies and percentages are given for qualitative variables. Non-parametric Binomial Chi-Square test was applied to observe within group associations and $p < 0.05$ was considered statistically significant. **Results:** Among 84 patients, 13 (15.5%) proved to be normally ganglionic whereas 71 (84.5%) showed ganglion related enteric neuronal abnormalities namely isolated hypoganglionosis 9 (12.7%), immaturity of ganglion cells 9 (12.7%), isolated hyperganglionosis (IND Type B) 2 (2.8%) and Hirschsprung's disease 51 (71.8%). Among HD group, 34 (66.7%) belonged to isolated form and 17 (33.3%) showed combined ganglion related abnormalities. **Conclusions:** Hirschsprung's disease is common in Pakistani population, followed by hypoganglionosis, immaturity of ganglion cells and IND type B. The presence of hypertrophic nerve fibres was significant in HD, hyperganglionosis and hypoganglionosis, whereas, no hypertrophic nerve fibres were appreciated in immaturity of ganglion cell group.

Keywords: Hirschsprung's disease (HD), hypoganglionosis, immaturity of ganglion cells (IGC), intestinal neuronal dysplasia (IND)

INTRODUCTION

Congenital intestinal neuronal abnormalities have been classified as aganglionosis (Hirschsprung's disease, HD), hyperganglionosis (Intestinal Neuronal Dysplasia type B, IND Type B), hypoganglionosis, ganglion cell immaturity, combined forms and certain unclassifiable forms.¹ HD is a developmental disorder of enteric nervous system characterised by the absence of ganglion cells in submucosal (Meissner's) and myenteric (Aurbach's) plexuses of distal bowel. It extends proximally from internal anal sphincter for varying distances that result in functional obstruction caused by dysmotility of the diseased segment, lack of propagation of peristaltic waves into the aganglionic colon, abnormal or absent relaxation of this segment and of the internal anal sphincter.²

Intestinal Neuronal Dysplasia (IND) is a distinct clinical entity that is genetically different from HD.³ Hyperganglionosis was described with a total increase in the number of ganglia and ganglion cells per ganglion in the myenteric and submucosal plexuses in the colon of three patients with severe motility disturbances.⁴ These morphological features, called neuronal colonic dysplasia and later renamed as intestinal neuronal dysplasia, have been considered a developmental defect of the submucosal plexus.⁵ The

IND was classified into two distinct clinical and morphological subtypes: Type A occurs in less than 5% cases, and is characterised by congenital aplasia or hypoplasia of the sympathetic innervations. It presents acutely in the neonatal period with episodes of intestinal obstruction, diarrhoea, and bloody stools. In the Type B the clinical features are indistinguishable from HD. It is characterised by a malformation of the parasympathetic submucosal plexus and accounts for over 95% cases of isolated IND. The IND occurring in association with HD belongs to type B.⁶

When normal looking ganglion cells are present in the submucosa and intramuscular layers, their population is decreased; the disease is referred to as hypoganglionosis.⁷ More recently it has been classified as an isolated form and HD associated form. Isolated hypoganglionosis has been characterised by the deficiency of nerve cells in myenteric plexus and sometimes in the submucosal plexus. It may exist proximal to a segment of typical aganglionosis, the transitional zone in HD referred to as HD associated form.⁸

Immaturity of ganglion cells is characterised by the number of ganglion cells either being normal or slightly increased, whereas the nuclear size is small.⁹ Haematoxylin-eosin staining of the specimen

demonstrates normal number of ganglion cells, and immature ganglion cells, in which nuclear and nucleolar configurations are not clear.⁷

The purpose of the present study was to find the morphological patterns of ganglion related enteric neuronal abnormalities in children presented to the two large tertiary care hospitals.

MATERIAL AND METHODS

This descriptive study was performed in two paediatric referral centres between March 2009 and October 2009. The children (aged 0–13 years) who were brought to the outpatient and emergency for medical attention and whose parents gave written informed consent were enrolled. Inclusion criteria were clinical suspicion of HD, radiological investigations, children both males and females. Biopsies being inadequate or taken from anorectal transformation zone were excluded.

Each biopsy specimen was preserved in containers with 10% formaldehyde. Each specimen was processed for paraffin blocks, sectioned into 4 µm thick sections (n=12–15 cut serially) and stained using haematoxylin and eosin (H&E). All the sections were also stained with reticulin, PTAH, Gomori's Trichrome and Palmgren's method. These sections were examined by two histopathologists (NH and AHN) independently. The findings were recorded in a morphological Performa. All specimens were grouped based upon the presence, number and morphology of ganglion cells in these biopsies. The data was analysed using SPSS-17. Frequencies and percentages are given for qualitative variables. Non-parametric Binomial Chi-Square test was applied to observe within group associations, and $p < 0.05$ was considered significant.

RESULTS

A total of 92 patients were enrolled between March 2009 and October 2009. We excluded four in whom biopsies were inadequate or taken from anorectal transformation zone. Finally 84 patients with clinical features of HD were left for morphological examination. A total of 206 biopsies were obtained and examined from 84 children. Among these patients, 13 (15.5%) proved to be normally ganglionic on rectal/colonic biopsies (Figure-1) and 71 (84.5%) showed enteric neuronal abnormalities. Among the latter 71 patients, 9 (12.7%) belonged to isolated hypoganglionic group (Figure-2), 9 (12.7%) revealed immaturity of ganglion cells (Figure-3), 2 (2.8%) showed isolated hyperganglionosis (IND type B) (Figure-4); whereas 51 (71.8%) diagnosed as Hirschsprung's disease group (Figure-5). Among these 51 cases, 34 (66.7%) had isolated HD and 17 (33.3%) had combined entities. In the combined group, 11 (64.7%) showed hypoganglionosis associated with HD, 1 (5.9%) had hyperganglionosis and hypoganglionosis in proximal

parts, 3 (17.6%) had hyperganglionosis and 2 (11.8%) showed immaturity of ganglion cells in proximal parts.

In ganglionic group, 1 of the 13 patients showed hypertrophic nerve fibres ($p=0.002$). In HD group, 43 (84.3%) of the 51 had hypertrophic nerve fibres ($p < 0.001$) (Figure-6). In immaturity of ganglion cells, biopsies from 9 patients did not show hypertrophy of nerve fibres. In isolated hypoganglionic group, 8 (88.9%) of the 9 patients showed hypertrophic nerve fibres ($p < 0.001$). In associated hypoganglionic group, hypertrophic nerve fibres were present in biopsies from 12 patients. In IND type B group (both associated and isolated), biopsies from all the 6 patients had hypertrophic nerve fibres.

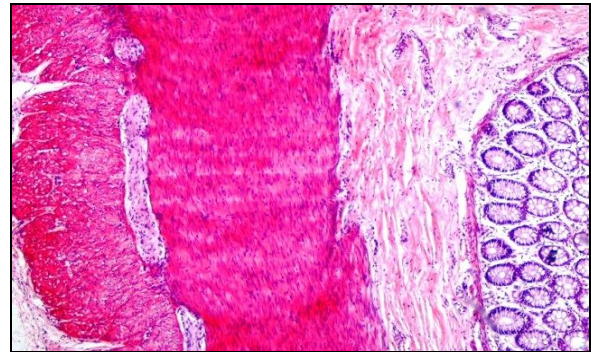


Figure-1: Normal ganglion cells in superficial sub-mucosal plexuses of colon (H&E ×200)

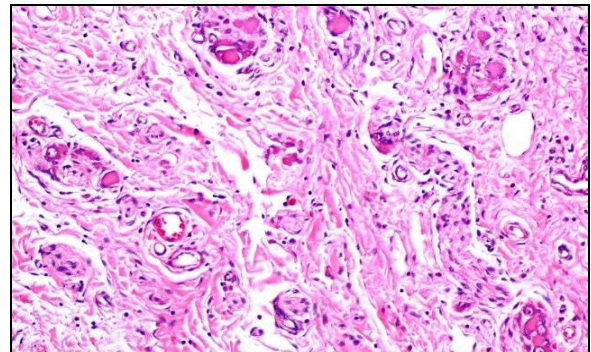


Figure-2: A single normal looking ganglion cell in muscular plexus along with increase in nerve cells in a case of hypoganglionosis (H&E ×100)

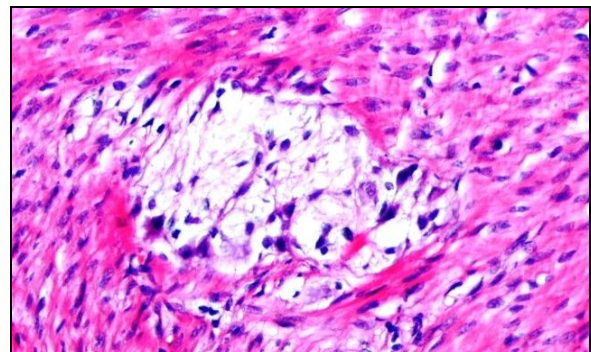


Figure-3: Immature ganglion cells in muscular plexuses of large intestine (H&E ×200)

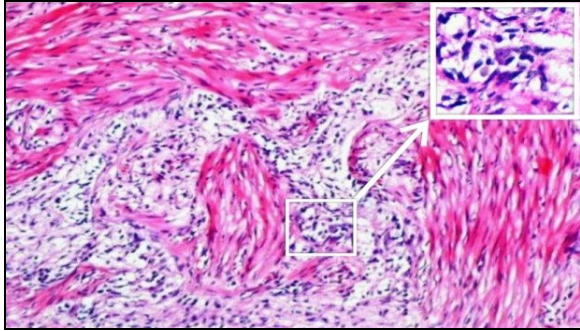


Figure-4: Numerous submucosal plexuses of colon in intestinal neuronal dysplasia type B (hyperganglioneosis). Hypertrophic nerve fibres are also present. (H&E ×100)

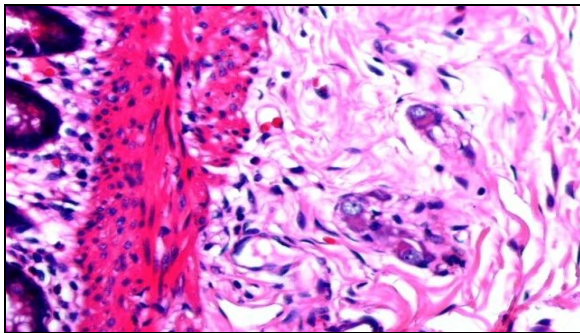


Figure-5: Full thickness of colon in a case of Hirschsprung's disease. Hypertrophic nerve fibres are also present in muscle layer (H&E ×40).

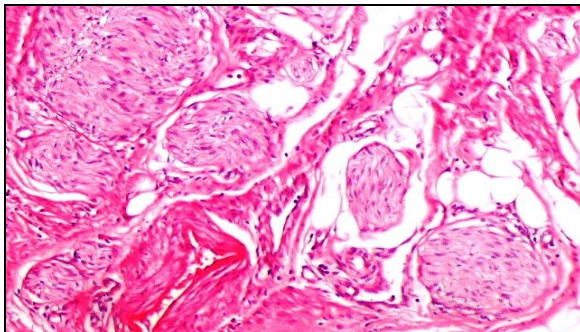


Figure-6: Hypertrophic nerve fibres in serosa in a case of Hirschsprung's disease. (H&E ×100)

DISCUSSION

In a series of 85 patients presented with bowel obstruction or chronic constipation, 21 (24.7%) were diagnosed HD, 2 (2.35%) with ultra-short segment HD (intestinal achalasia), 4 (4.7%) had IND type B and 58 (68.2%) had no neuromorphological alteration.¹⁰ IND Type A was diagnosed neither in this series nor in the present study. Another study on 19 paediatric patients showed that 1 (10%) had isolated hypoganglioneosis, 1 (8.3%) had isolated IND and 2 (15.4%) showed isolated immaturity of ganglion cells whereas the remaining 15 had combined neuronal abnormalities.¹¹ An Indian study reported 1 (2.78%) case of HD associated with IND and

6 (16.66%) with isolated IND.¹² The present study, on the other hand, shows that the frequency of HD associated with IND type B is much higher (11.8%) whereas isolated IND type B was only 2 (2.8%).

Isolated IND type B was found in 2.3% patients^{13,14} that is similar to our study. Intestinal neuronal dysplasia was reported to occur proximal to the aganglionic segment in 25–35% patients with HD (type B), and less frequently as an isolated disease¹ but in an Indian study it has been reported to be 2.78%¹².

The identification of neuronal abnormalities in proximal portion of aganglionic segment is important because ignoring it may result in inadequate resection leading to persistent bowel dysfunction after a pull through procedure. Adequate intraoperative evaluation of aganglionic segment, transitional zone and accompanying disorders, such as IND type B and/or hypoganglioneosis, is essential for the resection of length of the affected bowel to avoid recurrent constipation and necessity of reoperation.¹ Hypoganglioneosis associated with chronic faecal retention, similar to that seen in HD, is rare, accounting for only 5% of all classified congenital innervation defects of the colon.¹⁵ In another study on chronic refractory constipation, 18.2% cases were diagnosed as hypoganglioneosis¹⁴ that is higher than in the present study, i.e., 12.7%.

A study grouped ganglion cell immaturity as unclassifiable dysganglioneosis in 30 percent patients,¹⁶ however, another study reported 12.9% such cases¹⁷. The results of the latter study are similar to those in the present study (12.7%). Another study reported only 3.6% biopsies showing immaturity of ganglion cells.¹⁸

The present study, however, elicits that among the 84 patients who came with the features of HD, 13 (15.7%) showed normal ganglion cells on H and E stain. However, this incidence varies from 7% to 75% in different reports.^{14,19}

The absence of ganglion cells is the standard for the diagnosis of HD.^{20,21} The presence of hypertrophic submucosal nerve bundles was suggested as a helpful positive finding.^{22,23} A consensus on the diagnosis of HD was reported proclaiming that a combination of aganglioneosis and hypertrophic nerve trunk would be the diagnosis of HD.²⁴ In most of the previous studies, these criteria were supported^{1,12,25} but the number of cases fulfilling these criteria were not mentioned. In the present study, however, biopsies from 84.3% HD patients showed hypertrophic nerve fibres. Meier-Ruge¹⁶ concluded that immature submucosal plexus has rare developed nerve cells, which is similar to our study as no hypertrophy of nerve fibres demonstrated in this group.

Some reports were quoted regarding the presence of hypertrophic nerve fibres in colon of patients with hypoganglioneosis, in which thick nerve strands were observed;¹⁵ whereas it could not be noticed by

Watanabe *et al.*²⁶ In the present study we, however, observed that the presence of HNF in hypoganglionosis in submucosa and/or muscle layers was significant ($p < 0.001$).

The two obligatory criteria for the diagnosis of IND type B have been described as hyperplasia of the submucosal plexus and an increase in acetylcholinesterase stained positive nerve fibres around submucosal blood vessels.⁶ In this present paper we have reported an increase in hypertrophic nerve fibres on H and E stained sections in biopsies from all the 6 patients of IND Type B along with an increase in the number of ganglion cells.

CONCLUSIONS

We, therefore, conclude that in our study population, Hirschsprung's disease is most common among ganglion related enteric neuronal abnormalities followed by hypoganglionosis, immaturity of ganglion cells and intestinal neuronal dysplasia type B. The presence of hypertrophic nerve fibres was significant in HD, hypoganglionosis and IND type B groups whereas no hypertrophic nerve fibres were present in immaturity of ganglion cell group.

ACKNOWLEDGEMENTS

The authors are grateful to University of Health Sciences for funding this project. Mr. Sameer deserves special thanks for his help in processing of the tissues, and Mrs. Saadia Maqbool for composing this article.

REFERENCES

1. Dzienis-Koronkiewicz E, Dębek W, Chyczewski L. Clinical application of morphological methods for identification of intestinal nervous system elements. *Case Rep Clin Pract Rev* 2003;4:346–55.
2. de Lorijn F, Boeckxstaens GE, Benninga MA. Symptomatology, pathophysiology, diagnostic work-up, and treatment of Hirschsprung Disease in infancy and childhood. *Curr Gastroenterol Rep* 2007;9:245–53.
3. Tou JF, Li MJ, Guan T, Li JC, Zhu XK, Feng ZG. Mutation of RET proto-oncogene in Hirschsprung's disease and intestinal neuronal dysplasia. *World J Gastroenterol* 2006;12:1136–9.
4. Berry CL. Intestinal neuronal dysplasia: does it exist or has it been invented? *Virchows Archiv A Pathol Anat Histopathol* 1993;422:183–4.
5. Koletzko S, Jesch I, Faus-Kebetaler T, Briner J, Meier-Ruge W, Müntefering H, *et al.* Rectal biopsy for diagnosis of intestinal neuronal dysplasia in children: a prospective multicentre study on interobserver variation and clinical outcome. *Gut* 1999;44:853–61.
6. Puri P, Rolle U. Variant Hirschsprung's disease. *Semin Pediatr Surg* 2004;13:293–9.
7. Hayakawa K, Hamanaka Y, Suzuki M, Nakatsu M, Nishimura K, Tanaka M, *et al.* Radiological findings in total colon aganglionosis and allied disorders. *Radiat Med* 2003;21:128–34.
8. Zhang HY, Feng JX, Huang L, Wang G, Wei MF, Weng YZ. Diagnosis and surgical treatment of isolated hypoganglionosis.

- World J Pediatr 2008;4:295–300.
9. Taguchi T, Masumoto K, Leiri S, Nakatsuji T, Akiyoshi J. New classification of hypoganglionosis: congenital and acquired hypoganglionosis. *J Pediatr Surg* 2006;41:2046–51.
10. Bagdzevičius R, Vaičekauskas V, Bagdzevičiūtė S. Experience of acetylcholinesterase histochemistry application in the diagnosis of chronic constipation in children. *Medicina (Kaunas)* 2007;43:376–84.
11. Kim HK, Cheong H, Kang H, Bae JY, Song DE, Min SC, *et al.* Histopathological Evaluation of Pediatric Intestinal Pseudo-Obstruction: Quantitative Morphometric Analysis of Pathological Changes in the Enteric Nervous System. *Korean J Pathol* 2010;44:162–72.
12. Bandyopadhyay R, Chatterjee U, Basu AK, Banerjee S. Morphometry of nerve trunks in Hirschsprung's disease. *J Indian Assoc Pediatr Surg* 2003;8:195–201.
13. Meier-Ruge WA, Ammann K, Bruder E, Holschneider AM, Schärli AF, Schmitteneber PP, *et al.* Updated Results on Intestinal Neuronal Dysplasia (IND B). *Eur J Pediatr Surg* 2004;14:384–91.
14. Tomita R, Munakata K, Howard ER, Fujisaki S. Histological studies on Hirschsprung's disease and its allied disorders in childhood. *Hepatogastroenterology* 2004;51:1042–4.
15. Kobayashi H, Yamataka A, Lane GJ, Miyano T. Pathophysiology of Hypoganglionosis. *J Pediatr Gastroenterol Nutr* 2002;34:231–5.
16. Meier-Ruge W. Epidemiology of congenital innervation defects of the distal colon. *Virchows Archiv A Pathol Anat Histopathol* 1992;320:171–7.
17. Schärli AF. Neuronal intestinal dysplasia. *Pediatr Surg Int* 1992;7:2–7.
18. Markiewicz-Kijewska M, Kowalski A, Bacewicz L, Drewniak T, Ismail H, Kluge P, *et al.* Immaturity of ganglion cells - a study of our own material. *Polski Przegląd Hirurgiczny* 2009;81:95–102.
19. Berger S, Linke F, Tiling SV, Kap-herr SH. The clinical relevance of non-classified dysganglionoses and implications for a new grading system. *Pediatr Surg Int* 2002;18:361–7.
20. Monforte-Munoz H, Gonzalez-Gomez I, Rowland JM, Landing BH. Increased submucosal nerve trunk caliber in aganglionosis: A "positive" and objective finding in suction biopsies and segmental resections in Hirschsprung's disease. *Arch Pathol Lab Med* 1998;122:721–5.
21. Mudassara, Anwar-ul-Haque. Evaluation of serosal nerves in Hirschsprung Disease. *Int J Pathol* 2005;3:21–4.
22. Babu MK, Kini U, Das K, Alladi A, D'Cruz AJ. A modified technique for the diagnosis of Hirschsprung disease from rectal biopsies. *Natl Med J India* 2003;16:245–8.
23. Kakita Y, Oshiro K, O'Briain S, Puri P. Selective demonstration of mural nerves in ganglionic and aganglionic colon by immunohistochemistry for Glucose Transporter-1 prominent extrinsic nerve pattern staining in Hirschsprung Disease. *Arch Pathol Lab Med* 2000;124:1314–9.
24. Martucciello G, Pratob AP, Puri P, Holschneiderd AM, Meier-Ruge W, Jasonnib V, *et al.* Controversies concerning diagnostic guidelines for anomalies of the enteric nervous system: A report from the fourth International Symposium on Hirschsprung's disease and related neurocristopathies. *J Pediatr Surg* 2005;40:1527–31.
25. Howard ER, Garrett JR, Kidd A. Constipation and congenital disorders of the myenteric plexus. *J R Soc Med* 1984;77:13–9.
26. Watanabe Y, Ito F, Ando H, Seo T, Kaneko K, Harada T, *et al.* Morphological investigation of the enteric nervous system in Hirschsprung's Disease and hypoganglionosis using whole-mount colon preparation. *J Pediatr Surg* 1999;34:445–9.

Address for Correspondence:

Dr. Nausheen Henna, Department of Morbid Anatomy and Histopathology, University of Health Sciences, Lahore, Pakistan. **Cell:** +92-331-4380139
Email: noor_ul_hijab@hotmail.com