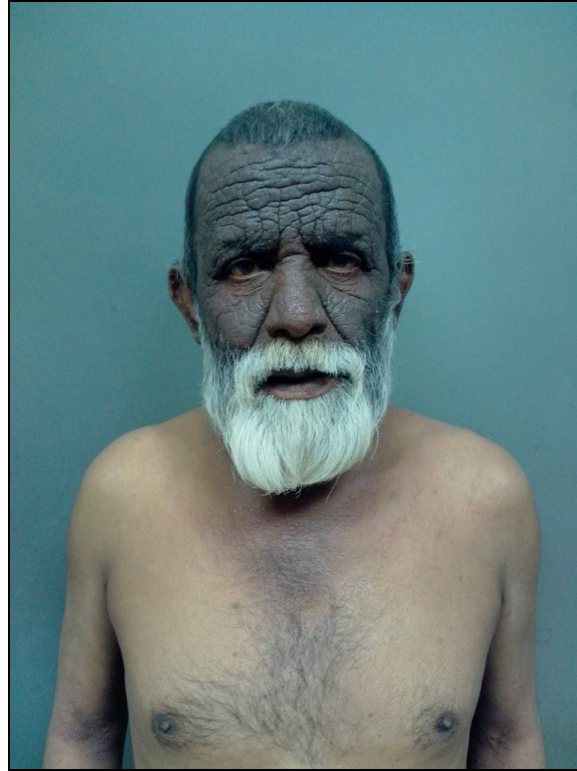


PICTORIAL

CHRONIC ACTINIC DERMATITIS

Shahbaz Ali Khan, Munir Ahmad Abbasi*

Department of Neurosurgery, *Department of Pulmonology, Ayub Medical College, Abbottabad, Pakistan



A 54 years old farmer from a hilly area with a pruritic and erythematous eruption on his face, neck, upper chest, and arms for the last 5 years, diagnosed as a case of Chronic Actinic Dermatitis.

Chronic Actinic dermatitis is a rare immune mediated photo-dermatoses that usually effects middle-aged or elderly males and is characterized by severe itching, red, inflamed, thickened and dry skin in the sun exposed areas. Treatment consists of advice on sunlight and allergen avoidance, topical corticosteroids and emollients. If the patient does not respond, systemic immune suppression may be considered: systemic prednisolone for acute exacerbations and azathioprine if long term systemic treatment is required.

<http://www.ayubmed.edu.pk/JAMC/26-1/Pictorial.pdf>

Address for Correspondence:

Dr. Munir Ahmad Abbasi, Department of Pulmonology, Ayub Teaching Hospital, Abbottabad, Pakistan

Cell: +92-333-440562

Email: munir.abbasi@gmail.com