

CASE REPORT

RETROPERITONEAL MASSES: DIFFERENT CLINICAL SCENARIOS

Badar Murtaza, Saira Saeed^{*}, Naser Ali Khan, Imran Bashir Malik^{}, Asad Mahmood[†],
Muhammad Ashraf Sharif^{††}, Ahsan Altaf Satti[‡]**

Department of General Surgery, ^{*}Gynae and Obstetrics, ^{**}Anaesthesia, [†]Medicine, ^{††}Pathology, [‡]Administration, Combined Military Hospital, Bahawalnagar Cantonment

We present two cases of retroperitoneal masses with different presentations and outcomes. The first case was a 22 years old primigravida lady who underwent emergency caesarean section for preterm premature rupture of membranes with breach. On the operating table, a large retroperitoneal mass was identified and the biopsy confirmed Burkitt's lymphoma. Post operative chemotherapy did not have a favourable result and the patient had a fatal outcome. The other case was a 15 years old boy who had a progressively increasing retroperitoneal mass. Exploratory laparotomy revealed a hard, fixed, unresectable tumour extending into the mesentery of the small gut, biopsies were taken which showed tuberculosis. Post operative antituberculosis treatment had a marked response and the tumour disappeared after 6 months.

Keywords: Retroperitoneal masses, Tumour

INTRODUCTION

Retroperitoneal masses are relatively uncommon. The diversity of the aetiology of these masses makes them even more interesting, however confusing as far as the management is concerned. The high proportion of soft tissue sarcomas found in the retroperitoneal space, necessitates early evaluation and prompt intervention in order to have encouraging results. Unfortunately these patients have late presentation even in the west, thus complete cure is not possible in a vast majority of cases.

The main problem of retroperitoneal masses is due primarily to their uninhibited growth with no facial boundaries, proximity to vital vascular and neural structures as well as intra-abdominal organs and to the large size attained before the development of symptoms and the establishment of a diagnosis. There are many causes of retroperitoneal masses; therefore it is imperative that a detailed patient's history, clinical examination, laboratory investigations and imaging techniques should be conducted for a definitive diagnosis. However there may be many occasions when a pre operative diagnosis cannot be reached and only a final diagnosis can be made on open surgery.

CASE REPORT

Case-1

An un-booked young primigravida lady, aged 22 years reported to the obstetrics emergency with preterm premature rupture of membranes and breach presentation. She had no previous visit to the antenatal clinic. However prior to this pregnancy she had been under treatment of a dermatologist for mucosal (oral) ulcerations for which she had received a course of steroids with partial response. Emergency caesarean section was decided by the obstetrician/gynaecologist after she had assessed the foetus on the

ultrasound. Lower segment caesarean section was performed under general anaesthesia. The procedure was uneventful, a healthy baby girl was delivered and the wound was closed in layers. Once the drapes covering the patient were removed a large mass was noted in the abdomen, extending from the diaphragm to the pelvis, predominantly on the left side and extending across the midline to the right side (Figure-1).

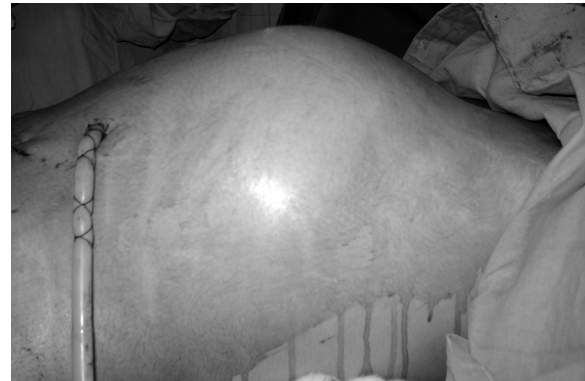


Figure-1: The large mass visible after the caesarean section and the removal of drapes

Accordingly the wound was reopened in order to assess the mass. The uterus was found well contracted and a large retroperitoneal hard, fixed, vascular tumour was encountered (Figure-2).

Biopsies were taken and the wound was closed in layers. The recovery from anaesthesia was slow but uneventful. The post operative period was also smooth. Histopathology report confirmed Burkitt's lymphoma. She was accordingly referred to the tertiary care oncology unit where she was evaluated in detail. Her CT scan chest was clear, abdominal CT scan confirmed the huge mass in the retroperitoneal region and pushing the gut to the right. Bone marrow trephine/biopsy did not reveal

any involvement. She was started on chemotherapy but the condition kept on deteriorating and the response to the initial therapy was not encouraging. She developed bilateral pneumonia with right pleural effusion requiring ventilatory support but the patient could not survive.

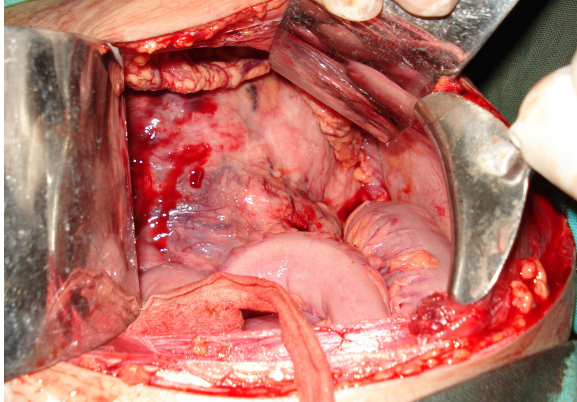


Figure-2: The large fixed and vascular retroperitoneal mass

Case-2

A male adolescent, aged 15 years, presented to the surgical outdoors with 1½ year history of progressively increasing abdominal mass with weight loss. There was no history of fever, constipation, vomiting, altered bowel habits or any urinary complaint. About 6 months back he was evaluated in detail at a tertiary care hospital. The complete blood count, urinalysis, liver/ renal function tests were normal. Ultrasound abdomen revealed a large 15×13 cm mass in the midline and left side of the abdomen (Figure-3).

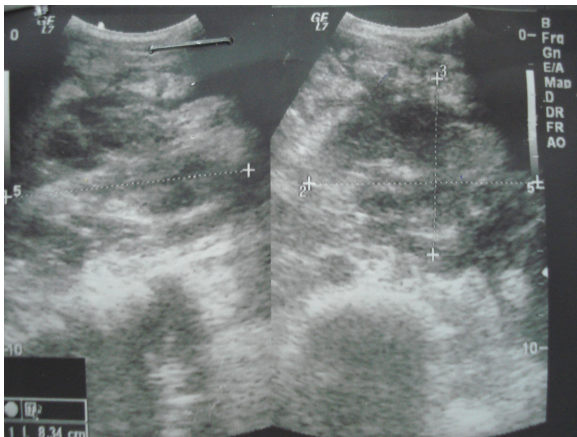


Figure-3: The retroperitoneal mass on the ultrasonography

The kidneys, liver and spleen were normal. CT scan abdomen confirmed a huge mass of mixed echogenicity not involving the gut, kidneys, ureters or major vessels (Figure-4).

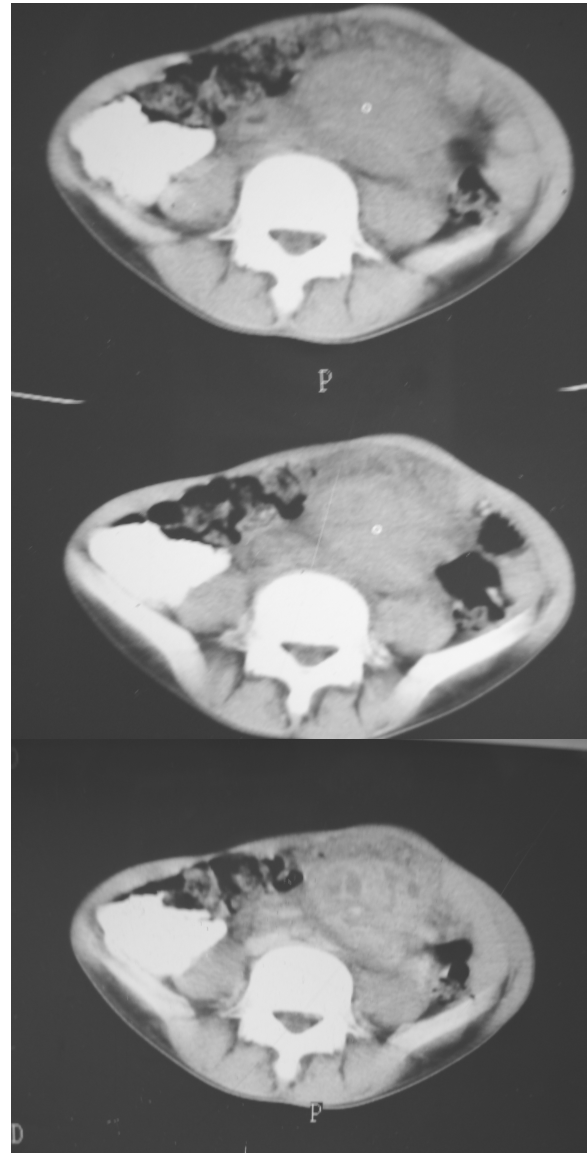


Figure-4: The CT scan views of the retroperitoneal mass

Fine needle aspiration cytology was attempted, but was inconclusive. Surgery was planned but the patient lost to follow up. After 6 months the patient reported to our surgical OPD. After preliminary baseline investigations, exploratory laparotomy was planned. A midline incision revealed a central/ midline tumour extending from the pancreas to the sacral promontory. It was a hard, fixed tumour extending into the mesentery of the whole of the small gut. No regional lymphadenopathy or involvement of liver/ spleen was noted. Accordingly biopsies were taken and the wound was closed in layers. The post operative recovery was smooth. The histopathology report unexpectedly confirmed chronic caseating granulomatous inflammation, most likely due to

tuberculosis. He was started on four drug antituberculosis treatment and made a dramatic recovery. He started gaining weight and clinical examination/ultrasonography after 6 months revealed no residual retroperitoneal mass. He was kept on the treatment for one year and is a healthy young adolescent man.

DISCUSSION

The diagnostic dilemma of retroperitoneal masses increases the interest of the clinician. A detailed evaluation may at times prove useless and only open biopsies may give some lead. The term retroperitoneal tumour is at times confined to the lesions arising from tissues (muscles, fat, fibrous tissue, lymph nodes, nerves and developmental remnants) of this compartment but excluding origin from the retroperitoneal organs. The retroperitoneal swellings may be cystic or solid, benign or malignant. The symptomatology varies but the most common presentation is with abdominal pain. The majority of solid retroperitoneal tumours are malignant (80%).¹ The benign tumours include leiomyomas, extra-adrenal chromaffinomas, mucinous cystadenomas and haemangiopericytomas, while the malignant tumours are lymphomas, soft tissue sarcomata, congenital neuroblastoma and neoplasms arising from the urogenital ridge.¹ However retroperitoneal masses may also develop as the benign or malignant lesions of the organs like, kidneys, adrenals, pancreas or ureters. The large masses formed by Burkitt's lymphoma and tuberculosis in the retroperitoneal space is not a common presentation.

Burkitt's lymphoma was first described in Eastern Africa, initially thought to be a sarcoma of the jaw.² Shortly it became well known that this was a distinct form of non-Hodgkin's lymphoma, in fact a primary high-grade B-cell lymphoma. Burkitt's lymphoma affects mainly children, and boys are more susceptible than girls. Apart from Epstein Bar virus, malaria and Human immunodeficiency virus (HIV) have shown association with Burkitt's lymphoma.³ It is a rare disease in adults in the United States, making up <1% of non-Hodgkin's lymphoma, but it makes up about 30% of childhood non-Hodgkin's lymphomas. In adults the median age is 31 years, predominantly affecting males (89%), mostly presenting in the stage I and stage II (62%) and a five years survival of 45%. Only 11% show gastrointestinal involvement and mostly present as an intra-abdominal mass arising from the ileocaecal region. It is an aggressive tumour which invades and permeates through the bowel wall at an early stage and is usually advanced at the time of presentation. The presentation with gastroduodenal disease is unusual and the endoscopic features are not characteristic. Burkitt's lymphoma as a retroperitoneal mass is quite rare and has not been documented in the

literature before. The endemic form of Burkitt's lymphoma occurs frequently in children in Africa, and the sporadic form in western countries. Immunodeficiency associated Burkitt's lymphoma is seen in patients with HIV infection. Once a suspicion of Burkitt's lymphoma is made, a definitive diagnosis should be reached promptly and staging evaluation must be accomplished expeditiously. This is the most rapidly progressive human tumour, and any delay in initiating therapy can adversely affect the patient's prognosis. Burkitt's lymphoma was one of the first cancers shown to be curable by chemotherapy. Today, cure can be expected in 70 to 80% of both children and young adults when effective therapy is administered precisely.⁴ Late presentation of this tumour and a heavy tumour load carry a bad prognosis. Salvage therapy has been generally ineffective in patients failing in the initial treatment, emphasizing the importance of the initial treatment approach. Our case not only presented very late with a huge mass probably hidden by the progressive pregnancy, also had a poor response to the initial treatment, thus resulting in fatality.

Tuberculosis is world-wide, but is particularly more common in Africa and Asia. In all nearly 2 billion people, a third of the world's population, are infected. The prevalence of tuberculosis increases with poor social conditions, inadequate nutrition and overcrowding.⁵ Tuberculosis was relatively uncommon in the west, but now with the people travelling all over the world, it is now more frequently seen in the west. Pulmonary tuberculosis is the most common form. However it can be found in any part of the body like ileocaecal region, kidneys, urinary bladder, epididymis, tubo-ovarian area, meninges, joints, bones, skin, pericardium and adrenals. The lymph node inflammation is another common mode of presentation. Any group of nodes may be involved, but hilar and paratracheal lymph nodes are commonly affected. In retroperitoneal area, tuberculosis can present as retroperitoneal tuberculous adenopathy, tuberculosis of retroperitoneal organs (like kidney, adrenals) or retroperitoneal fibrosis. However formation of a large tuberculous mass in the retroperitoneal area is a rare presentation. In our case the histopathology was suggestive of chronic caseating granulomatous lesion, however no lymphatic tissue was seen and secondly the lesion being in the midline and extending into the mesentery, most probably had developed in the retroperitoneal soft tissue and not from any specific organ. Retroperitoneal fibrosis, although rare, can develop as a result of peritoneal tuberculosis.⁶ Encapsulation of aorta (periaortitis) with narrowing by an abnormal soft tissue mass due to tuberculosis was documented by Molloy *et al.*⁷ Tuberculosis can

spread from the Pott's disease and form a psoas abscess, retroperitoneal inflammatory mass⁸ or even retroperitoneal fibrosis. Rare cases of retroperitoneal abscess due to empyema necessitates into the retroperitoneal space through the diaphragm has also been reported.⁹

Retroperitoneal masses are in fact diagnosed on laparotomy. Jazet *et al*¹⁰ documented two cases of retroperitoneal masses which presented as obstructive jaundice and haematemesis which were diagnosed as tuberculosis after diagnostic laparotomy. In fact tuberculosis should be considered in the differential diagnosis of all intra-abdominal as well as the retroperitoneal masses, especially in the areas like Asia and Africa.

REFERENCES

1. Cuschieri A, Steele RJC, Moossa AR. Essential surgical practice: Higher surgical training in general surgery. In: Cuschieri A. Disorders of abdominal wall and peritoneal cavity. 4th ed. London: Arnold Publishers, 2002;p.165-7
2. Mukerji PK, Hilfer CL. Burkitt's lymphoma with mandible, intra-abdominal and renal involvement- initial presentation of HIV infection in a 4-year-old child. *Pediatr Radiol* 1993;23(1):76-7.
3. Orem J, Mbiddle EK, Lambert B, de Sanjose S, Weiderpass E. Burkitt's lymphoma in Africa, a review of the epidemiology and etiology. *Afr Health Sci* 2007;7:166-75.
4. Kasper DL, Braunwald E, Fauci AS, Hauser SL, Longo DL, Jameson JL. Harrison's principles of internal medicine. In: Armitage JO, Longo DL. Malignancies of lymphoid cells. Vol 1. 16th ed. New York: McGraw-Hill Companies Inc, 2007;p. 648-52.
5. Kumar P, Clark M. Kumar and Clark clinical medicine. In: Finch RG, Moss P, Jeffries DJ, Anderson J. Infectious diseases, tropical medicine and sexually transmitted diseases. 5th ed. Edinburgh: Elsevier Science Limited 2002;p.88-9.
6. Greco P, Vaglio A, Cobelli R, Zompatori M, Buzio C. Tuberculosis as a trigger of retroperitoneal fibrosis. *Clin Infectious Dis* 2005;41:72-5.
7. Molloy CB, Filer C, Ismail A. Mycobacterium tuberculosis as a cause of chronic periaortitis. *Rheumatol* 2005;44:696-7.
8. Seth A, Ansari MS, Trikha V, Mittal R. Retroperitoneal fibrosis: a rare complication of Pott's disease. *J Urol* 2001;166:622-3.
9. Sakamoto T, Miyamoto Y, Nishio W, Matsuoka H, Tsubota N. Empyema necessitatis into the retroperitoneal space. *Ann Thorac Surg* 2002;73:1954-6.
10. Jazeta IM, Perkb L, de Roosc A, Bolka JH, Arend SM. Obstructive jaundice and hematemesis: two cases with unusual presentations of intra-abdominal tuberculosis. *Eur J Internal Med* 2004;15:259-61.

Address for Correspondence:

Dr. Badar Murtaza, Classified Surgical Specialist, 675 A, Mazhar Qayyum Road, Old Lalazar Colony, Rawalpindi, Pakistan. Tel: +92-51-5514862, Cell: +92-321-6911424
Email: badar_murtaza@yahoo.com