

## CORRELATION OF SEVERITY OF ST SEGMENT ELEVATION IN ACUTE INFERIOR WALL MYOCARDIAL INFARCTION WITH THE PROXIMITY OF RIGHT CORONARY ARTERY DISEASE

**Moazzam Ali Naqvi, Muzaffar Ali, Fuad Hakeem\*, Arslan Masood, Zubair Akram**

Department of Cardiology, Jinnah Hospital, Lahore, \*Punjab Institute of Cardiology, Lahore, Pakistan

**Background:** A number of researchers have used different electrocardiographical criteria to predict the culprit vessel in acute inferior wall myocardial infarction (MI) cases. Therefore, the determination of infarct related artery in AMI is extremely important with regard to prediction of potential complications, furthermore, predicting the probable site of occlusion within RCA is worthwhile because proximal occlusions are likely to cause greater myocardial damage and an early invasive strategy may be planned in such cases. Our study aimed at evaluating the ECG criteria to predict the proximity of lesion in the right coronary artery (RCA) in acute inferior wall MI cases. The Objectives were to predict the presence of a proximal lesion in right coronary artery by severity of ST segment elevation in inferior ECG leads. This cross-sectional study carried out at the department of cardiology and cardiac catheterization at Jinnah Hospital, Lahore from April 2008 to September 2008. **Methods:** A total of 60 patients who suffered from inferior wall MI were included in the study who underwent coronary angiography in the first week. The ECGs of these patients were then compared with the angiographic findings to correlate the proximity of culprit lesion in RCA with the degree of ST segment elevation in inferior limb leads. **Results:** Out of 60 patients, 29 (48.4%) had the culprit lesion in proximal, 23 (38.5%) in mid and 8 (13.4%) in distal RCA. Patients with proximal RCA disease showed a mean ST segment elevation of  $12.55 \pm 1.38$  mm, with mid RCA disease  $8.39 \pm 0.89$  mm and with distal RCA disease  $6.0 \pm 0.54$  mm. **Conclusion:** This study demonstrated that the severity of ST segment elevation was correlated with proximity of RCA lesion **Keywords:** Right coronary artery, ST elevation MI, Acute Myocardial infarction

### INTRODUCTION

Acute myocardial infarction (AMI) is a common disease with serious consequences in mortality, morbidity, and cost to the society. Coronary atherosclerosis plays a pivotal part as the underlying substrate in many patients.<sup>1</sup> Acute myocardial infarction has always been a potential health problem due to the life-threatening complications.<sup>2</sup> About 1/3 of inferior wall MI cases have concomitant right ventricular infarction.<sup>3</sup> Myocardial infarction results from prolonged myocardial ischemia precipitated in most cases by an occlusive coronary thrombus at the site of a pre-existing atherosclerotic plaque. More rarely, infarction may result from prolonged vasospasm, inadequate myocardial blood flow or excessive myocardial demand. Very rarely myocardial infarction may be caused by embolic coronary occlusion, vasculitis, coronary artery dissection or aortitis. Certain risk factors predisposed to AMI which are categorized as modifiable (smoking, hypertension, dyslipidemia, obesity, physical inactivity and diabetes) and non-modifiable (age, sex and family history of heart disease).<sup>4</sup>

In 80% of acute inferior wall myocardial infarction cases the infarct related artery is right coronary artery (RCA), while it is left circumflex artery in the rest.<sup>5</sup> The incidence of mortality and complications are high in patients of acute inferior wall MI with right ventricular involvement.<sup>6</sup> Acute inferior

myocardial infarction (AIMI) is sometimes complicated by hypotension and arrhythmias. In the presence of complications, RCA is generally the infarct related artery. Therefore, the determination of infarct related artery in AMI is extremely important with regard to prediction of potential complications, furthermore, predicting the probable site of occlusion within RCA is worthwhile because proximal occlusions are likely to cause greater myocardial damage and an early invasive strategy may be planned in such cases. Electrocardiogram (ECG) is an important tool in determining the therapeutic strategy in acute coronary syndromes. The ECG usually confirms diagnostic features in half of the cases with AMI.<sup>7</sup>

The severity of ST segment elevation (STSE) is well known to be related to the extent of infarction and prognosis.<sup>8</sup> In this study, the severity of STSE and the proximity of culprit lesion along the infarct related artery was investigated in patients with AIMI.

### MATERIAL AND METHODS

This cross-sectional study was conducted at Cardiology Department, Jinnah Hospital, Lahore from April to September 2008. We included 60 patients of either gender irrespective of age, who fulfilled the inclusion criteria and underwent coronary angiography within a week's time, after suffering from acute inferior wall myocardial infarction. An informed consent was obtained from each patient before inclusion in the study.

The study included patients admitted in CCU or emergency with acute inferior wall MI that was defined as raised cardiac biomarkers in the presence of ST elevation of  $\geq 1$  mm in at least 2 of the inferior leads and reciprocal ST segment depression in leads I and aVL. In each case a single value of ST segment elevation was obtained by addition of amplitudes (mm) of ST segment elevation in inferior leads 0.08 sec after the J-point. The ECGs were recorded by Kenz Cardio 302 triple-channel machine and were analyzed by two investigators blinded to each other. Patients with previous history of ischemic heart disease were excluded from the study. Also, cases in which RCA was found to be non-dominant on angiography or in which left circumflex was found to be the culprit vessel were excluded from the study.

A coronary angiography via Judkins technique was performed in all these patients after stabilization in the first week and reported by two cardiologists blinded to each other. Coronary angiographies were carried out under Infinix CS Toshiba Model-2000. The lesion with highest degree of stenosis along RCA was accepted as the culprit lesion. Right coronary artery was divided into proximal, mid and distal segments. The segment of RCA from its ostium to the origin of first acute marginal branch was considered proximal, from the origin of first acute marginal to that of last acute marginal branch was considered mid and from this point onwards as distal.

Data was analyzed by computer software SPSS version 12. Categorical variables were expressed as numbers and percentages, while continuous variables were expressed as Mean $\pm$ SD. Mean ST elevation was compared between proximal, middle and distal lesions. For comparison between proximal versus middle, middle versus distal and proximal versus distal lesions, *t*-test was applied and a *p*-value of  $\leq 0.05$  was considered statistically significant. For combined comparison, ANOVA was used as test of significance. Pearson product correlation was estimated and regression curve was analysed for finding the association of location of coronary artery lesion and ST elevation.

## RESULTS

The study included 43 males (72%) and 17 (28%) females. Thirty patients (50%) had diabetes mellitus, 27 (45%) patients were hypertensive, 10 patients (17.7%) had family history of ischemic heart disease and 2 (3.3%) patients had dyslipidemia (Table-1). Out of 60 patients, 29 (48.4%) had the culprit lesion in proximal, 23 (38.5%) in mid and 8 (13.4%) in distal RCA. Patients with proximal RCA disease

showed a mean ST segment elevation of  $12.55 \pm 1.38$  mm, with mid RCA disease  $8.39 \pm 0.89$  mm and with distal RCA disease  $6.0 \pm 0.54$  mm. In our study there were ST segment elevations in leads II, III and aVF along with reciprocal ST depressions in leads I and aVL. In this study ST elevation in lead III was more than that in lead II. Acute inferior wall MI was complicated by right ventricular infarction (RVI) in 20 patients, of whom 18 had the culprit lesion in Proximal RCA. Fifteen patients suffered from atrioventricular (AV) blocks, out of which 11 had the culprit lesion in proximal RCA.

By applying *t*-test, total ST elevation in inferior leads was found to be significantly higher in proximal RCA lesions as compared to mid RCA ( $p < 0.01$ ) (Table-2), similarly, significantly higher in mid RCA as compared to distal RCA lesions ( $p < 0.01$ ) (Table-3) and significantly higher in Proximal RCA as compared to distal RCA lesions ( $p < 0.01$ ) (Table-4). The maximum amplitude of ST elevation in inferior leads was found to be significantly associated with the proximity of right coronary artery lesion confirmed by coronary angiography.

Combined analysis for Proximal, Mid and Distal RCA lesions was carried out using ANOVA test (Figure-1). The total ST elevation showed decreasing trends with lesion progression from proximal to distal location within the RCA.

**Table-1: Baseline characteristics of the patients**

Age (years)	54.07 $\pm$ 10.97
Males	43 (72.0%)
Females	17 (28.0%)
Diabetes Mellitus	30 (50.0%)
Hypertension	27 (45.0%)
Family history of ischemic heart disease	10 (17.7%)
Dyslipidemias	2 (3.3%)

**Table-2: Comparison of mean ST elevation for Proximal and Mid RCA lesions**

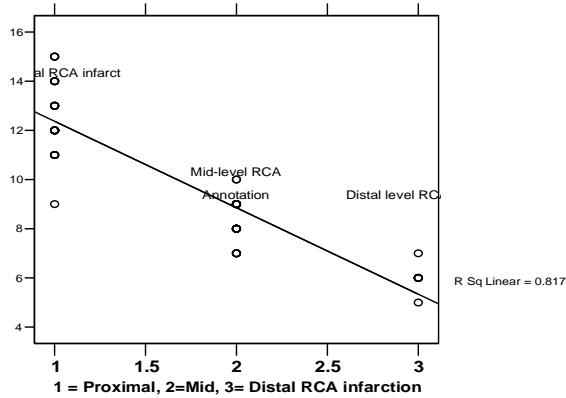
Angiography lesions	N	ST Score (mm)	SD	<i>p</i> -value
Proximal RCA	29	12.55	1.38	<0.01
Mid RCA	23	8.39	0.89	

**Table-3: Comparison of mean ST elevation for Mid and Distal RCA lesions**

Angiography status	N	ST Score (mm)	SD	<i>p</i> -value
Mid RCA	23	8.39	0.89	<0.01
Distal RCA	8	6.00	0.54	

**Table 4 - Comparison of mean ST elevation for Proximal and Distal RCA lesions**

Angiography status	N	ST Score (mm)	SD	<i>p</i> -value
Proximal RCA	29	12.55	1.38	<0.01
Distal RCA	8	6.00	.54	



Pearson Product correlation = -0.90 (*p* value for ANOVA is significant at 0.01)

**Figure-1: Combined comparison of Proximal, Mid and Distal RCA lesions**

## DISCUSSION

Despite the presence of breakthrough in therapeutic strategies for acute coronary syndrome, AMI has been an important cause of morbidity and mortality. Half of AMI related deaths generally occur in the first hour and are usually due to the ventricular arrhythmias. The initiation of immediate and effective therapy has considerably decreased the mortality rates of AMI.<sup>9</sup>

In addition to the occlusion of RCA, the proximity of the culprit lesion along the course of RCA is also important with regards to the potential complications (SA node dysfunction, RV infarction etc.) in the setting of acute inferior-wall MI. Right ventricular myocardial infarction is associated with increased risk of death, shock, ventricular tachycardia or fibrillation and atrioventricular blocks.<sup>10</sup> Though the frequency of RCA stenosis is high, RVI occurs less commonly than would be anticipated. This discrepancy is most likely related to the lower oxygen demands of the RV and a prominent inter-coronary collateral system.<sup>11,12</sup>

Inferior wall MI due to RCA occlusion frequently presents with ST elevation in leads II, III and aVF with reciprocal ST segment depression in leads I and aVL.<sup>13</sup> In the past few years several investigators have proposed various criteria for identifying the infarct related artery in patients presenting with inferior wall MI. Co-existence of conditions including myocarditis, pericarditis, early repolarisation and electrolyte disturbances may adversely affect the prediction of infarct related artery.<sup>7</sup> Zimetboun *et al* showed that higher ST elevation in lead III more than that in lead II was only seen in RCA occlusions<sup>14</sup> and Chia *et al* reported that ST elevation in lead III more than that in lead II was valuable in predicting RCA occlusion.<sup>15</sup> Similar

criteria to predict the RCA occlusion in acute inferior wall MI was also confirmed by Yokousoglu *et al* with a positive predictive value of 78.9%, sensitivity of 89.4% and specificity of 50%.<sup>16</sup> Our study showed similar results. Berry *et al* also showed that ST depression in both aVL and V1 was a marker of RCA occlusion in acute inferior wall MI.<sup>17,18</sup> Fiol Mikual *et al* showed that the sum of ST depression in I and aVL compared to criteria based on ST depression in aVL was more specific for RCA.<sup>19</sup> Similar results were obtained in our study. In association to determining the infarct related artery in acute inferior wall MI, the proximity of culprit lesion along the course of RCA is very significant with regard to complications. Therefore it is important to predict the proximity of RCA with certain ECG criteria. In our study a greater degree of ST segment elevation was observed in patients with proximal RCA lesion as compared to those with mid or distal RCA lesions. Similar results were observed by Alim Erdem *et al*.<sup>8</sup>

Frequency of RVI associated with inferior wall MI was 33% (20) in this study compared with 28% cases of right ventricular infarct associated with inferior wall infarction in study carried by M Ali *et al*.<sup>20</sup> Zehander *et al*<sup>21</sup> found an incidence of 27% of RVI based on electrocardiographic criteria.

The ECG criteria to differentiate between RCA and LCX as the culprit vessel in the setting of acute IWMI are well established.<sup>22</sup> In the present study, the correlation of maximum ST segment elevation in the inferior leads demonstrated well the proximity of culprit lesion along right coronary artery.

## CONCLUSION

In the setting of acute Inferior-wall MI, the severity of ST segment elevation and the proximity of the culprit lesion along the infarct-related right coronary artery were found to be closely related.

## STUDY LIMITATIONS

This study was carried out on a relatively small number of patients and it is possible that just one false positive result might change the level of significance while comparing the two groups. Hence, in order to obtain more accurate results larger group of patients should be included in future studies.

## REFERENCES

1. Boersma E, Mercado N, Poldermans D, Gardien M, Vos J, Simoons ML. Acute myocardial infarction. *Lancet* 2003;361:847-58.
2. Correale E, Battista R, Martone A, Pietropaolo F, Ricciardiello V, Digirolamo D, *et al*. Electrocardiographic patterns in acute inferior myocardial infarction with and without right ventricle involvement: classification, diagnostic and prognostic value, masking effect. *Clin Cardiol* 1999;22:37-44.
3. Khan S, Kundi A, Sharieff S. Prevalence of right ventricular

- myocardial infarction in patients with acute inferior wall myocardial infarction. *International Journal of Clinical Practice* April 2004;58:354-7.
4. Iqbal MJ, Azhar M, Javed MT, Tahira I. Study on ST-segment elevation acute myocardial infarction in diabetic and non-diabetic patients. *Pak J Med Sci* 2008;24:786-91.
  5. Berger PB, Ryan TJ. Inferior myocardial infarction: high risk subsets. *Circulation* 1990;81:401-11.
  6. Khan A, Raza A, Khan AAU, Aziz A, Yousaf M. Incidence and clinical implication of right ventricular infarct. *Pak Armed Forces Med J* 1993;43(1):32-4.
  7. Antman EM, Braunwald E. Acute myocardial infarction. In: Braunwald E, Zipes DP, Libby P, editors. *Heart disease. A textbook of cardiovascular medicine*. 8<sup>th</sup> ed. Philadelphia: WB Saunders Company, 2008;p 1135-9.
  8. Candan I, Oral D, editors. *Kardiyoloji*. 1<sup>st</sup> ed. Ankara: Ankara Tip Yaymlan;2002.
  9. Galla JM, Mukherjee D. Complications of myocardial infarction. In: Griffin BP, Topol EJ, editors. *Manual of cardiovascular medicine*. 3<sup>rd</sup> ed. Philadelphia: Lippincott Williams & Wilkins, 2009;p 48-66.
  10. Manka R, Fleck E, Paetsch I. Silent inferior myocardial infarction with extensive right ventricular scarring. *Intern J Cardiol* 2008;127:e186-7.
  11. Samadikhah J, Hakim SH, Asl AA, Azarfarin R, Ghaffari S, Khalili A. Arrhythmia and conduction disorders in acute inferior myocardial infarction with right ventricular involvement. *RMJ* 2007;32:135-8.
  12. Bayram E, Atalay C. Identification of the culprit artery involved in inferior wall acute myocardial infarction using electrocardiographic criteria. *J Int Med Res* 2004;32:39-44.
  13. Zimetbaum PJ, Krishnan S, Gold A, Carrozza JP, Josephson ME. Usefulness of ST-segment elevation in Lead III exceeding that of lead II for identifying the location of the totally occluded coronary artery in inferior wall myocardial infarction. *Am J Cardiol* 1998;81:918-9.
  14. Chia BL, Yip JW, Tan HC, Lim YT. Usefulness of ST elevation II/III ratio and ST deviation in lead I for identifying the culprit artery in inferior wall acute myocardial infarction. *Am J Cardiol* 2000;86:341-3.
  15. Sag C, Ozkan M, Uzun M, Yokusoglu M, Baysan O, Erinc K, *et al*. Relationship between coronary risk calculation and distribution of the coronary artery lesions and risk factors. *Anadolu Kardiyol Derg* 2006;6:353-7.
  16. Berry C, Zalewski A, Kovach R, Savage M, Goldberg S. Surface electrocardiogram in detection of transmural myocardial ischemia during coronary artery occlusion. *Am J Cardiol* 1989;63:21-6.
  17. Cadwell MA, Froelicher ES, Drew BJ. Prehospital delay time in acute myocardial infarction: an exploratory study on relation to hospital outcomes and cost. *Am Heart J* 2000;139:788-96.
  18. Fiol M, Carrillo A, Cygankiewicz I, Ayestarán J, Caldés O, Peral V, *et al*. New criteria based on ST changes in 12-Lead surface ECG to detect proximal versus distal right coronary artery occlusion in a case of acute inferoposterior myocardial infarction. *Ann Noninvasive Electrocardiol* 2004;9:383-8.
  19. Erdem A, Yilmaz MB, Yalta K, Turgut OO, Tandogan I. The severity of ST segment elevation in acute inferior myocardial infarction: Does it predict the presence of a proximal culprit lesion along the right coronary artery course? *Anadolu Kardiyol Derg* 2007;7:189-90.
  20. Ali M, Rana SI, Shafi S, Nazeer M. In hospital outcome of acute inferior wall MI with or without right ventricular infarction. *Ann King Edward Med Coll* 2004;10:420-2.
  21. Zehnder M, Kasper WW, Kander E, Schonhaler M, Olschewskim, Just H. Comparison of diagnostic accuracy, time dependency and prognostic impact of Q waves. Combined electrocardiographic criteria and ST segment abnormalities in right ventricular infarction. *Br Heart* 1994;72:119-24.
  22. Clinical interpretation and significance of ST changes. In: Luna AB, Sala MF, Antman EM, editors. *The 12-Lead ECG in ST elevation myocardial infarction*. Massachusetts: Blackwell Publishing, 2007;p 15-54.

### Address for Correspondence:

**Dr. Muazzam Ali Naqvi**, FCPS (Med), MOF-I, GOR-III, Shadman Lahore. Cell: +92-300-4791419

**Email:** moazzamalinaqvi@yahoo.com