

## CASE REPORT

# TWO-PORT LAPAROSCOPIC CHOLECYSTECTOMY— A NEW TECHNIQUE

**SH Waqar, Syed Fahad Shah, Irshad Ali Khan, Tanveer Sadiq Ch, M Tariq Abdullah,  
Zafar Iqbal Malik, MA Zahid**

Minimal Access Surgery Unit (MASU), Department of General Surgery, Pakistan Institute of Medical Sciences, Islamabad

Laparoscopic cholecystectomy is now the procedure of choice in all the gall bladder diseases and there is increase in the skills of surgeons with newer equipment. Normally the laparoscopic cholecystectomy is performed by using four ports or three ports. Two ports laparoscopic cholecystectomy is rarely performed as it demands greater expertise and skills. Also this technique is less expensive and less scar formation than four port laparoscopic cholecystectomy. We present a case of a middle aged female who underwent successfully laparoscopic cholecystectomy by using only two ports.

**Keywords:** Laparoscopic cholecystectomy, Gall bladder.

## INTRODUCTION

Laparoscopic cholecystectomy is the gold standard treatment of gall bladder diseases all over the world today. The operation is routinely performed using four or three ports of entry into the abdomen.<sup>1</sup> Recent developments regarding LC have been directed towards reducing the size or number of ports to achieve the goal of minimal access surgery. Two-port laparoscopic cholecystectomy has been reported in the international literature to be safe and feasible.<sup>2</sup> To our knowledge, two-port laparoscopic cholecystectomy is not yet reported in national literature. We modified the four-port laparoscopic cholecystectomy and presented first time in Pakistan a case report of new innovative two-port method of gall bladder removal.

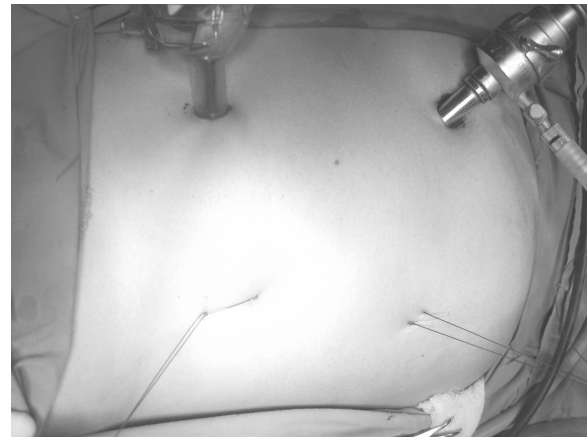
## CASE REPORT

A 37 years old female presented in surgical out-patient department with symptoms of pain right hypochondrium off and on associated with dyspepsia for last two years. She was investigated and diagnosed as a case of cholelithiasis. She was married and had Caesarean Section through pfennestil incision six years back. Laparoscopic cholecystectomy was planned. We developed a new technique of laparoscopic cholecystectomy by using only two ports of entry into the abdomen. In this operation, only the supraumbilical port (10 mm) and the epigastric port (10 mm) were used for access. The gall bladder was manipulated through strategically placed two traction sutures, passed through the fundus and the neck of the gall bladder, respectively. (Figure-1) Surgery was performed successfully and recovery was smooth. (Figure-2) The operating time was 50 minutes. She was allowed orally after four hours and was discharged from the hospital next day.

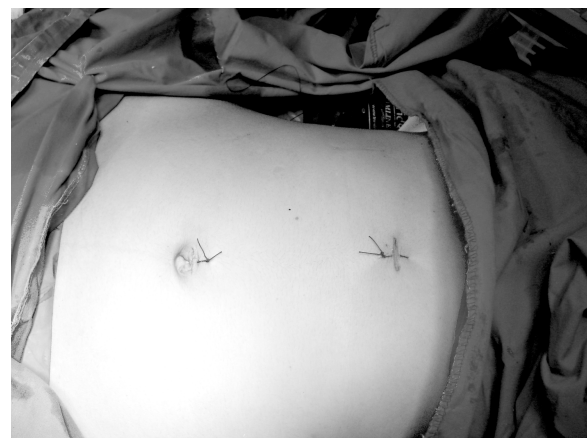## DISCUSSION

In the era of minimal access surgery, the outcomes we consider are not only the safety, but also quality,

which is often defined by pain and cosmetic results. Scar less surgery is the ultimate goal for both surgeons and patients.



**Figure-1: During operation**



**Figure-2: After operation**

Two-port laparoscopic cholecystectomy has shown a higher patient's satisfaction score.<sup>3</sup> However, whether it offers any additional advantages remains controversial<sup>2</sup>. A report on two-port laparoscopic cholecystectomy has already shown that

all patients would choose two-port over four-port approach<sup>4</sup>. Similarly in our case, the postoperative pain was significantly reduced and the procedure was cosmetically more acceptable to the patient.

Two-port laparoscopic cholecystectomy has been reported to be safe and feasible, but it is technically difficult even in expert hands because of small operative field. Poon CM *et al* have modified the operating telescope to achieve a wide field of view.<sup>3</sup> They have modified the operating telescope to allow a wide operative field and reported their initial results of two-port laparoscopic cholecystectomy. We have performed successfully our case by using zero degree telescopes.

Numbers of different techniques are developed and are being used by laparoscopic surgeons all over the world. Ng WT described laparoscopic cholecystectomy via a

one-port incision; however, the single wound is, in fact, merely the result of combining the camera and adjacent 10-mm working ports.<sup>5</sup> Tagaya N *et al* reported a new technique of laparoscopic cholecystectomy by two-port approach using abdominal wall lifting method.<sup>6</sup> They noticed that retraction of the gall bladder is possible by the insertion of forceps through the umbilical port along the telescope which might eliminate the necessity of creating the third port. T Kagaya developed a "Twin-port" system that allows a 5-mm camera and a forceps to be inserted through a single port for laparoscopic cholecystectomy procedure. A 5 mm trocar is inserted approximately 1 cm below the

xiphoid process, and the laparoscopic cholecystectomy is performed via two ports.<sup>7</sup> Mishra has developed a unique technique with extra corporeal knot to perform this two port laparoscopic cholecystectomy surgery. Lee KW reported a two-port needlescopic cholecystectomy using 2-mm or 3-mm endograspers.<sup>8</sup> We performed our case using two traction sutures passed through the fundus and the neck of the gall bladder, respectively with good results.

## REFERENCES

1. Ramachandran CS, Arora V. Two-port laparoscopic cholecystectomy: an innovative new method for gall bladder removal. *Laparoendosc Adv Surg Tech A*. 1998;8:303-8.
2. Poon C M, Chan K W, Lee D W H, Chan K C, Ko C W, Cheung H Y, Lee K W. Two-port vs four-port laparoscopic cholecystectomy: A prospective randomized controlled trial. *urg Endosc* 2003;17:1624-7, epub 2003 July 21.
3. Poon C M, Chan K W, Lee D W H, Chan K C, Ko C W, Cheung H Y, Lee K W. *Journal of Laparoendoscopic & Advanced Surgical Techniques*. 2002;2:259-2.
4. Leung KF, Lee KW, Cheung TY, Leung LC, Lau KW. Laparoscopic cholecystectomy: two-port technique. *Endoscopy* 1996;28:505-7.
5. Ng WT, Kong CK, Wong YT. One-wound laparoscopic cholecystectomy. *Br J Surg* 1997;84:1627.
6. Tagaya N, Fukutomi K, Kogure H. New Two-Port Technique for Laparoscopic Cholecystectomy. A Preliminary Report *Dokkyo J Med Sci* 1999;26:419-22.
7. Kagaya T. Laparoscopic Cholecystectomy via two port using the "Twin-port" system. *J Hepatico-Biliary-Panct Surg* 2001;8:76-80.
8. Lee KW, Poon CM, Leung KF, Lee DWH, Ko CW. Two-port needlescopic cholecystectomy: prospective study in 100 cases. *Hong Kong Med J* 2005;11:30-5.

## Address for Correspondence:

**Dr. SH Waqar**, House # 385, Street # 29, Sector G-8/2, Islamabad, Pakistan. Tel: +92-51-2280500, Cell: +92-3335131365

**Email:** drshwaqar@gmail.com