

NASAL HIRUDINIASIS —AN UNUSUAL CAUSE OF EPISTAXIS

Sheikh Saadat Ullah Waleem, Saeed Ullah*

Department of ENT, Combined Military Hospital, Muzaffarabad, *Combined Military Hospital, Abbottabad

Background: Common causes for unilateral nasal bleeding in adults are benign or malignant tumours, deviated nasal septum, nasal trauma and foreign bodies. Nasal leech infestation has not been identified as a cause of nasal bleeding in most of the textbooks of Ear Nose and Throat. Over 3 years, at Combined Military Hospital Muzaffarabad, and Combined Military Hospital Abbottabad, we have dealt with 38 such cases presenting with epistaxis where the cause was found to be leech infestation. **Methods:** A descriptive study was carried out at Combined Military Hospital Muzaffarabad and Combined Military Hospital Abbottabad over a period of 3 years. All patients whose epistaxis was due to leech infestation were included in the study regardless of age and sex. **Results:** A total of 38 such cases presented with nasal Hirudiniasis as a cause of unilateral epistaxis. 29 were male and 09 female. All of the patients related their problem to the intake of fresh water of stream origin. The mean duration of symptoms was 12 weeks SD 3.0. **Conclusion:** It is concluded that nasal Hirudiniasis (nasal leech infestation) is a cause of unilateral epistaxis in areas like Muzaffarabad, Azad Kashmir and Abbottabad, where leeches are a common inhabitants of fresh water streams.

Keywords: Unilateral epistaxis, Nasal Hirudiniasis, Human leech infestation, Nasal bleeding

INTRODUCTION

Epistaxis is a common complaint to the Ear Nose and Throat clinic. Epistaxis results from the interaction of factors that damage the nasal mucosal lining, affect the vessel walls, or alter the coagulability of the blood, and which may be categorized into environmental, local, systemic and medication related¹⁰. Unilateral epistaxis is commonly due to foreign bodies, vascular trauma or benign or malignant neoplasm². Parasitic infestation is a rare cause, the most important being myiasis. Leech infestation (Hirudiniasis) has not been mentioned as a common cause of unilateral epistaxis in the text books. We have noted that leech infestation may be a 'not so uncommon' cause of unilateral nasal bleeding and must be added into the causal list of unilateral epistaxis, at least in areas like Azad Jammu Kashmir and Hazara where natural sources of water are infested with leeches.

MATERIALS AND METHODS

This descriptive study was carried out at Combined Military Hospital Muzaffarabad and Combined Military Hospital Abbottabad over a period of 03 years from July, 2006 to June, 2009. All patients whose epistaxis was due to leech infestation were included in the study. Patients having other causes of epistaxis were excluded. Patients having leech infestation at places other than nose were also excluded. Patients of both gender and all age groups were included. At the end of 3 yrs data revealed that a total of 38 such cases were dealt with at both these Military Hospitals. Detailed clinical examination with a good light source was the main diagnostic tool for the diagnosis of leech infestation. Leech inside the nasal cavity was mainly diagnosed by anterior and/or posterior rhinoscopy. In one case it was the indirect laryngoscopy that revealed a leech in the

larynx and in another it was the torch examination that revealed a leech sitting on the posterior pharyngeal wall. Though these are worth mentioning the two cases were excluded from the study as we are reporting 'nasal Hirudiniasis' only. In most of the cases we were successful in removing the leeches alive, in one piece (Figure-1-2) whereas rarely it broke into pieces and had to be removed piecemeal. In all cases the diagnosis was confirmed by removal of the causative organism, i.e., leech. Forceps were used to hold onto the leech and pull gently till it let go of the host mucosa. Most of the cases did not require any type of anaesthesia for removal however in a few 4% lignocaine spray was used for surface anaesthesia. No irritative or paralysing chemical agents were used on the leech. The data was entered and analysed on SPSS 10.

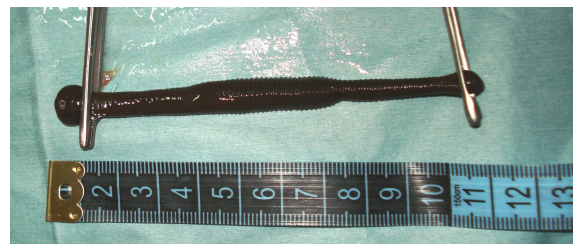


Figure-1: A live 11 cm leech removed from right nostril



Figure-2: Leech removed with the help of forceps

RESULTS

A total of 38 such cases presented with nasal Hirudiniasis as a cause of unilateral epistaxis. 29 were male and 9 female. In 36 cases we were able to remove the leech alive whereas in 2 cases it broke into pieces and had to be removed piecemeal. All of the patients related their problem to the intake of fresh water of stream origin. Most of the patients presented to us with history of bleeding from one side of the nose, severe irritation inside the nose, unilateral blockade which was intermittent incomplete, sense of something moving inside the nose and a few have seen the leech inside their nose with their own eyes or observed by their relatives. The mean duration of symptoms was 12 weeks SD 3.0.

Table-1: Symptomatology of Nasal Hirudiniasis

Symptoms	No. of patients	%
Nasal obstruction	29	76.31%
Nasal irritation	34	89.47%
Unilateral bleeding	36	94.73%
Something moving inside the nose	26	68.42%
Foreign body sensation nose	9	23.68%

DISCUSSION

Hirudiniasis is the term used to indicate leech invasion into a body orifice or cavity. Leeches are annelids belonging to the subgroup Hirudinea.¹ Based on the habitat of the leeches the leeches may be classified as Fresh water leeches, Terrestrial leeches and Marine leeches. All leech species are carnivorous feeding on a variety of invertebrates like worms, snails etc. A few are haemorrhagic parasites in nature feeding on blood of animals. Leeches attach themselves to humans. They are capable of sucking blood. Land leeches have powerful jaws and attach to skin; aquatic leeches have weak jaws and can only attach to soft tissues. Common species that can infest humans are *Dinobdella ferox*, *Hirudinea granulosa* and *Hirudinea viridis*.² Leeches are generally found in puddles of water and streams. When water is drunk from these streams and puddles, leeches can infest the human body; they can then be located anywhere in the upper respiratory tract from the nose to the larynx. They adhere to the mucosa with the anterior sucker and they live on blood here. All of our 38 cases used to drink water from fresh water streams which are quite a common practice in Azad Jammu Kashmir and Hazara area. In addition to these 38 cases we had one where the leech was attached to the larynx and another where it was attached to the posterior pharyngeal wall causing severe irritating cough.

The saliva of leech contains a local anaesthetic that limits the sensation of the host. The host doesn't attempt to dislodge the leech because there is no sensation. The saliva also contains a potent vasodilator that dilates the blood vessels enabling the leech to feed on the increased blood supply. Another important

constituent of its saliva is 'hirudin' which is a potent anticoagulant and prevents blood from clotting. The last two factors are mainly responsible for epistaxis. Leech bites cause intense itching which is responsible for severe sense of irritation inside the nose.

In tropical regions, leech bites on the skin are a common event. However, serious consequences of leech bite injury to the internal viscera are uncommon.³ If they do occur, they can cause significant morbidity and may even be fatal.⁴ Leech bite to various sites (e.g., the nose, pharynx, larynx, oesophagus, rectum, vagina and bladder) have been reported sporadically in the literature.⁵⁻⁷ The morbidity associated with a leech bite is mainly due to 2 factors: mechanical obstruction of a vital organ and/or severe bleeding. The prolonged bleeding after a leech bite is due to the action of factors in the leech saliva left in the bite, which include histamine-like vasodilators, hirudin (a potent antithrombin), hyaluronidase, and calin (a platelet aggregation inhibitor)^{8,9} and this may be the main cause of epistaxis. That was why nose bleed was the most common symptom in our patients. Interaction between exposed collagen and platelet and/or von Willebrand factor is believed to be one of the initiating events for thrombus formation at the site of damaged endothelium. Interference with this mechanism may provide an antithrombotic potential. Calin specifically inhibits human platelet aggregation induced by collagen.¹⁰ In addition, it has been shown that calin inhibits platelet adhesion.^{9,11} Because of these factors bleeding from a leech bite wound has been reported to persist for a mean of 10 hours and as long as 7 days.¹² However none of our case had such an episode of prolonged bleeding and though the presentation was of on and off nose bleed, none lasted for more than a few minutes. Indeed, for the above mentioned reasons, medicinal leeches are used to treat venous congestion because of their ability to remove excess blood and temporarily increase blood flow within compromised tissue.⁸ Direct removal of a live leech might be difficult because of its powerful attachment to the mucosa and its slimy and mobile body. Application of saline or menthol solution irritates whereas lignocaine paralyses the leech and may be helpful in removal. In our study it was not our practice to use any irritating or paralyzing agent on the leech however in a few cases surface anaesthesia with 4% lignocaine had to be used in uncooperative patients. Nasendoscopy has been reported to be the best procedure for locating and removing leeches from nose. However neither we had the equipment nor did we require it in any of the case. The leech should not be forcibly removed because its jaws may remain in the wound, causing prolonged bleeding and infection.¹³

Bleeding from a leech bite can be severe, requiring blood transfusion, and it can produce shock.^{4,6,14} In all of our cases none had such a severe

bleeding so as to require nasal packing. Xylometazoline hydrochloride 1:1,000 nasal sprays was advised post removal to promote vasoconstriction of nasal mucosa and minimise bleeding and it worked well in all cases. None of our patient had anaemia severe enough to require blood transfusion.

CONCLUSION

Nasal infestation by leech is not an uncommon cause of unilateral epistaxis and should be included in the differential diagnosis especially in leech endemic areas. There is need to educate people living in these areas about the possible complications of drinking untreated, unhealthy water directly from stream sources and measures should be taken to ensure provision of disease free drinking water to all.

REFERENCES

1. Deka PM, Rajeev TP. Unusual cause of hematuria. *Urol Int* 2001;66:41-2.
2. Gangadharan S KS, Rajeshwari A. An unusual foreign body in the nose. *Gujarat J Otolaryngol Head Neck Surg* 2005;2:21-2.
3. Bergua A, Vizmanas F, Monzon FJ, Blasco RM. Unavoidable epistaxis in the nasal infection of leeches. *Acta Otorrinolaringol Esp* 1993;44:391-3.
4. Cundoll DB, Whitehead SM, Hechtel FO. Severe anaemia and death due to pharyngeal leech myxobdella Africana. *Trans R SOC Trop Med Hyg* 1986;80:940-4.
5. Kruger C, Malleyeck I, Olsen OH. Aquatic leech infestation: a rare cause of severe anemia in an adolescent Tanzanian girl. *Eur J Pediatr* 2004;163:297-9.
6. Raj SM, Radzi M, Tee MH. Severe rectal bleeding due to leech bite. *Am J Gastroenterol* 2000;95:1607.
7. Hamid MS, Mohd Nar GR. Severe urological complication of leech bite in the tropics. *Br J Urol* 1996;77:164-5.
8. Munro R, Hechtel FO, Sawyer RT. Sustained bleeding after a leech bite in the apparent absence of hirudin. *Thromb Haemost* 1989;61:366-9.
9. Conforti ML, Connor NP, Heisey DM, Hartig GK. Evaluation of performance characteristics of the medicinal leech (*Hirudo medicinalis*) for the treatment of venous congestion. *Plast Reconstr Surg* 2002;109:228-35.
10. Munro R, Jones CP, Sawyer RT. Calin –a platelet adhesion inhibitor from the saliva of the medicinal leech. *Blood Coagul Fibrinolysis* 1991;2:179-84.
11. Deckmyn H, Stassen JM, Vreys I, Van Houtte E, Sawyer RT, Vermylen J. Calin from *hirudo medicinalis*, an inhibitor of platelet adhesion to collagen, prevents platelet-rich thrombosis in hamsters. *Blood* 1995;85:712-9.
12. Hernandez M, Ramirez Gutierrez RE. Internal Hirudiniasis: vaginal bleeding resulting from leech bite. *Ginecol Obstet Mex* 1998;66:284-6.
13. Ikizceli I, Avsarogullar L, Sozuer E, Yurumez Y, Akduz O. Bleeding due to a medicinal leech bite. *Emerg Med* 2005;22:458-60.
14. Hailemariam B. Post menopausal vaginal bleeding due to vaginal wall leech infestation. *Ethiopian Medical Journal*. 1995;33:183-5.

Address for Correspondence:

Dr. Saeed Ullah, Classified ENT Specialist, ENT Department, Combined Military Hospital, Abbottabad, Pakistan.

Cell: +92-333-6866608

Email: saeedyz@yahoo.com