

ORIGINAL ARTICLE

ACUPUNCTURE TREATMENT OF FACIAL PALSY

Syed Zahid Hussain Bokhari, Syeda Samina Zahid*

Pain and Plegia Centre, Dabgari Gardens Peshawar, *Khyber Girls Medical College Hayatabad Peshawar, Pakistan

Background: Bell's palsy is an idiopathic, acute peripheral-nerve palsy involving the facial nerve which supplies all the muscles of facial expression. This study was conducted to evaluate the effects of Electro-Acupuncture on patients with Facial Palsy. **Methods:** This study was conducted on patients with facial palsy at a private clinic at Peshawar during 1999–2009, and 49 cases were included in the study. All those cases that were within first two weeks of illness or who had related history of stroke or they had upper motor neuron lesion were not included in the study. Electro-acupuncture was used as the main therapeutic technique to treat these cases. Patients were subjected to acupuncture treatment at four major points on the face for 20–25 minutes everyday for 10 days. Specific points were used for nasolabial fold and watering of the eye. After rest for a week patients were again evaluated and another course of treatment comprising of 5–10 days was sufficient in most cases. Frequency of electro-acupuncture is kept at 60–80 cycles per minute.

Results: Total number of patients studied was 49 with duration of illness as early as 3 weeks to a year and above. Cases with duration of illness from 3 weeks onward showed rapid recovery of palsy symptoms with electro-acupuncture. All cases showed recovery. Palsy of the angle of the mouth did not recover completely. **Conclusion:** Electro-acupuncture is effective in treating facial palsy cases.

Keywords: Facial palsy, Bell's palsy, Electro-acupuncture

INTRODUCTION

Bell's palsy is an idiopathic, acute peripheral-nerve palsy involving the facial nerve which supplies all the muscles of facial expression. Bell's palsy is named after Sir Charles Bell (1774–1842), who first described the syndrome along with the anatomy and function of the facial nerve. Affected patients develop unilateral facial paralysis over 1–3 days with forehead involvement and no other neurologic abnormalities. Patients with Bell's palsy typically complain of weakness or complete paralysis of all the muscles on one side of the face. The facial creases and nasolabial fold disappear, the forehead unfurrows, and the corner of the mouth droops. The eyelids will not close and the lower lid sags. On attempted closure, the eye rolls upward (Bell's phenomenon). Eye irritation often results from lack of lubrication and constant exposure. Tear production decreases, however, the eye may appear to tear excessively because of loss of lid control, which allows tears to spill freely from the eye. Food and saliva can pool in the affected side of the mouth and may spill out from the corner.¹

Symptoms typically peak in the first week and then gradually resolve over 3 weeks to 3 months. Bell's palsy has been traditionally defined as idiopathic; however, one possible aetiology is infection with herpes simplex virus type-1. A common short-term complication of Bell's palsy is incomplete eyelid closure with resultant dry eye. A less common long-term complication is permanent facial weakness with muscle contractures.

Approximately 70–80% of patients will recover spontaneously; however, treatment with a 7-day course of acyclovir or Val-acyclovir along with prednisone typically prescribed in a 10-day tapering course starting at 60 mg per day, initiated within 3 days of the onset of symptoms, is recommended to reduce the time to full recovery and increase the likelihood of complete recuperation.² The incidence of Bell's palsy is 15–30 per 100,000 persons, with equal numbers of men and women affected. There is no predilection for either side of the face. Patients who have had one episode of Bell's palsy have an 8% risk of recurrence.^{3,4}

Patients with Bell's palsy usually progress from onset of symptoms to maximal weakness within 3 days and almost always within one week. Left untreated, 85% of patients will show at least partial recovery within 3 weeks of onset.⁵ Bell's palsy is believed to be caused by inflammation of the facial nerve at the geniculate ganglion, which leads to compression and possible ischemia and demyelination. In upper motor neuron lesion affecting the facial nerve causing facial palsy will not paralyse the forehead on the affected side, resulting in a unilateral facial paralysis with forehead sparing.

Acupuncture is a technique that has proved effective in treating palsy cases. In WHO's recommendations facial palsy is a diseases in which acupuncture form of treatment is effective. It is an old technique of traditional Chinese medicine that is now being vastly studied in the western world in the medical sectors as alternative medicine and has been introduced as alternative treatment in many diseases.⁶ Fine filiform needles are used at acupuncture points

that are explained on different parts of body. In old traditional technique hand stimulation was used to achieve the desired effects.

Electro-acupuncture is a relative modern innovation. In electro-acupuncture stimulators are used to give pulsatile stimulation parting passive contractions to muscles/group of muscles. Electro acupuncture achieves early results in certain conditions and is specifically indicated in treatment of palsies and in pain management.^{7,8} TENS is innovation from principles of acupuncture. This technique is crude with compromised results and thus has limited application.

MATERIAL AND METHODS

Majority of cases that reported to us had been diagnosed as Bell’s palsy cases by their physicians. They had already undergone conventional treatment of steroids and had been subjected to varied durations of physiotherapy. Most of them had passed the acute stage and had partial recovery of different symptoms. These were those leftover cases in which recovery had standstill or was very slow. Few cases found their way to our clinic in early stage of disease. (Table-1)

Table-1: Total number of cases and duration of illness

Total Cases	3-4 weeks	5-30 weeks	31-45 weeks	1 year and above
49	18	25	4	2

The cases diagnosed as Bell’s palsy by physicians and treated on conventional methods but without recovery were included in this study. Cases with unilateral facial palsy were included. Only those cases that had passed into 3rd week of illness and had not shown signs of recovery were included in this study. All those cases of facial palsy that had related history of stroke or upper motor neuron lesion and cases of Bell’s palsy in first 2 weeks of illness were excluded. A referred case of traumatic facial palsy with history of head injury was also not included in this study.

The patients were subjected to electro-acupuncture at four points: Jiache (S6) Dicang (S4) (Corresponding to buccinator and angle of the mouth), and Zanzhu (B2), Sizhukong (SJ23) (corresponding to eyebrow). Yanbai (G14) Yifeng (SJ17), and Jingming (B1) were used for weakness of occipitofrontalis, nasolabial fold and watering of the eye respectively (Figure-1).

Daily stimulation was given for 20-25 minutes. Frequency was kept at 60-80 cycles per minute. Treatment was given for 10 days. Patient is then given rest for a week. Improvement is evaluated at the end of this period. Second course of treatment

ranging from 5-10 days was then given in the light of residual disability. In most of the cases this treatment regimen was sufficient. These patients were prescribed methylcobalamin one injection daily for five days at the commencement of treatment.

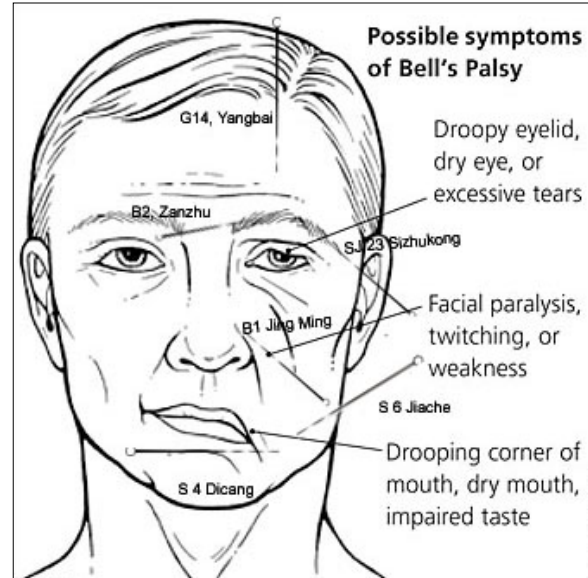


Figure-1: Needle insertion shown at the acupuncture points

(Adopted from American Family Physician Vol: 76, No. 7)

RESULTS

All the 49 cases treated had satisfactory recovery within a very short time span of two weeks. Long standing cases in which recovery had virtually stopped or was very slow, in them recovery was expedited and was satisfactorily completed in two weeks (Table-2).

In the recovery phase, the symptoms of collection of food underneath the effected cheek recovered completely within a week of treatment. Closure of the eye was symptom next to recover. Watering of affected eye and drooping at the nasolabial fold required specific points for treatment and they responded well. Frowning of the forehead showed moderately good recovery. Recovery of this symptom was taken as the limiting point to stop further treatment. Angle of mouth showed partial recovery. This required long term management as residual symptoms persist giving mild to moderate cosmetic effects and grin on the effected side is not completely restored. All cases recovered from disability (Table-3).

Table-2: Duration of illness and response to electro-acupuncture treatment in Bell’s palsy

Duration of illness	Response
First week	No
Second week	Slow
3-4 weeks	Good
5 weeks and beyond	Good

Table-3: Response to treatment in specific facial muscles in patients of Bell's palsy with duration of illness from third week onwards

Muscles	Buccinator	Orbicularis oculi	Risorius, Orbicularis Oris	Occipito-frontalis
Response	Good	Good	Very slow	Slow
Recovered in	5–10 sittings	10–15 sittings	Full recovery not achieved*	10–20 sittings
Symptom recovered	Collection of food under cheek on the effected side is relieved	Closure of the eye is achieved and watering of the eye is relieved	Angle of the mouth is partially restored in place	Frowning of the forehead on the effected side is gradually achieved

*Residual symptoms persist, causing mild to moderate cosmetic effect at the angle of the mouth.

DISCUSSION

Bell's palsy has a fair prognosis without treatment, with almost three quarters of patients recovering normal mimetical function and just over a tenth having minor sequelae. In patients who recover without treatment, major improvement occurs within 3 weeks mostly. Inflammation of the nerve initially results in a reversible neurapraxia, but ultimately Wallerian degeneration ensues. If recovery does not occur within this time, then it is unlikely to be seen until 4–6 months, when nerve re-growth and re-innervation have occurred.⁹ Patients who have complete facial palsy, who have no recovery by three weeks or who have suffered from herpes zoster virus (Ramsay Hunt Syndrome) have poor prognosis in Bell's palsy. Untreated Bell's palsy leaves some patients with major facial dysfunction and a reduced quality of life.

A Study evaluated 2,570 persons with untreated facial nerve palsy, including 1,701 with idiopathic (Bell's) palsy and 869 with palsy from other causes; 70% had complete paralysis. Function returned within three weeks in 85% of patients, 29% of patients had sequel.⁵ However, patients who have incomplete recovery will have obvious cosmetic sequel and will often be dissatisfied with their outcome.¹⁰ Some published studies have reported benefit with acupuncture versus steroids and placebo, but all had serious flaws in study design and reporting.¹¹

Among the medicinal treatment steroids and antiviral drugs are prescribed within 72 hours of Bell's palsy and are reported with mixed effects.^{12,13} Till date physiotherapy has been only option and even in that, options are limited to transcutaneous electrical stimulation with uncertain effects.¹⁴

In our study the effect of electro-acupuncture that is a simple physical treatment technique has proved most effective in restoring functions in different muscles that were affected by

facial palsy. This has been indicated in various studies.^{1–11,15–19}

It seems that the facial nerve suffers neurapraxia and stands a good chance at recovery when treated by electro acupuncture in recovery phase. This will specially prevent the left out cases going into Wallerian degeneration as the time factor towards recovery is the most important factor preventing complication such as permanent facial weakness with muscle contractures. We studied the results in patients with Bell's palsy with duration of illness from 3 weeks onward. We limited our observation of response to treatment in cases, from third week onwards as this is the time period when the nerve is in the recovery phase and the results are uniform. Electro-acupuncture restored the normal function in all forty-nine cases. It is thus indicated that a new algorithm be established and following antiviral and steroid therapy in patients of facial palsy electro-acupuncture therapy be introduced in the recovery phase for optimum and early results. Thirty-one cases had fallen in the time period from 5th week onwards. Up to 3 weeks is the time period that is considered in most studies as the period of spontaneous recovery. Beyond this, cases are considered as having gone into sequel. For these cases conventional form of treatment have no effective valid options. All these cases responded to treatment and recovered. This confirms affectivity of electro-acupuncture in treating facial palsy.

CONCLUSION

Electro acupuncture is effective in restoring functions of muscles affected in facial palsy. In the new algorithm, following antiviral and steroid therapy patients failing to show recovery of facial palsy may be subjected to electro-acupuncture treatment in the recovery phase, i.e., third week onwards, for optimum and early recovery.

REFERENCES

1. Tiemstra JD, Khatkhate N. Bell's Palsy: Diagnosis and Management. *Am Fam Physician* 2007;76:997–1002.
2. Bell's palsy. Available at: <http://www.ninds.nih.gov/disorders/bells/bells.htm>.
3. Gildeen DH. Clinical practice. Bell's palsy. *N Engl J Med* 2004;351:1323–31.
4. Morris AM, Deeks SL, Hill MD, Midroni G, Goldstein WC, Mazzulli T, *et al*. Annualized incidence and spectrum of illness from an outbreak investigation of Bell's palsy. *Neuroepidemiology* 2002;21:255–61.
5. Peitersen E. Bell's palsy: the spontaneous course of 2500 peripheral facial nerve palsies of different etiologies. *Acta Otolaryngol Suppl* 2002;549:4–30.
6. Bokhari Z, Zahid S. The role of acupuncture in arthritis of the knee joint in addition to local steroid injection. *J Postgrad Med Inst* 2006;20(1):36–9.
7. Bokhari Z, Zahid S. Pain management in Lumbago: role of acupuncture in addition to local steroid infiltration at trigger points. *J Postgrad Med Inst* 2007;21(2):141–5.

8. Bokhari Z, Zahid S. Treatment of frozen shoulder. *J Postgrad Med Inst* 2009;23(2):184–8.
9. Holland NJ, Weiner GM. Recent developments in Bell's palsy: Clinical review. *BMJ* 2004;329:553–7.
10. Gillman GS, Schaitkin BM, May M, Klein SR. Bell's palsy in pregnancy: a study of recovery outcomes. *Otolaryngol Head Neck Surg* 2002;126:26–30.
11. He L, Zhou D, Wu B, Li N, Zhou MK. Acupuncture for Bell's palsy. *Cochrane Database Syst Rev* 2004;1:CD 002914.
12. Hato N, Yamada H, Kohno H, Matsumoto S, Honda N, Gyo K, *et al.* Valacyclovir and prednisolone treatment for Bell's palsy: a multicenter, randomized, placebo-controlled study. *Otol Neurotol* 2007;28:408–13.
13. Sullivan FM, Swan IR, Donnan PT, Morris JM, Smith BH, McKinstrv B, *et al.* Early Treatment with prednisolone or acyclovir in Bell's palsy. *N Eng J Med* 2007;357:1653–5.
14. Ohtake PJ, Zafron ML, Poranki LG, Fish DR. Does electrical stimulation improve motor recovery in patients with idiopathic facial (Bell) palsy? Evidence in Practice. *Phys Ther* 2006;86:1558–64.
15. Li Y, Liang FR, Yu SG, Li CD, HuL X, Zhou D, *et al.* Efficacy of Acupuncture and moxibustion in treating Bell's palsy. A multicentre randomized controlled trial in China. *Chin Med J (Engl)* 2004;117:1502–6.
16. Nippon, Jiblin Koka, Gakkal, Kaiho. Acupuncture and moxibustion in treating Bell's palsy. *Chin Med J (Engl)* 2007;110:592–8.
17. Wang S, Hu HC, Wang DS. Randomized controlled study on reinforcing method of acupuncture for treatment of Bell's palsy at restoration stage. *Zhongguo Zhen Jiu* 2008;28:111–3.
18. Zhang D. A method of selecting acupoints for acupuncture treatment of peripheral facial paralysis by thermography. *Am J Chin Med* 2007;35:967–75.
19. Fu XH. Observation on therapeutic effect of acupuncture on early peripheral facial paralysis. *Zhongguo Zhen Jiu*. 2007;27:494–6.

Address for Correspondence:

Dr. Syed Zahid Hussain Bokhari, Pain and Plegia Centre, Dabgari Gardens, Peshawar, Pakistan.

Email: zhbphs@yahoo.com